

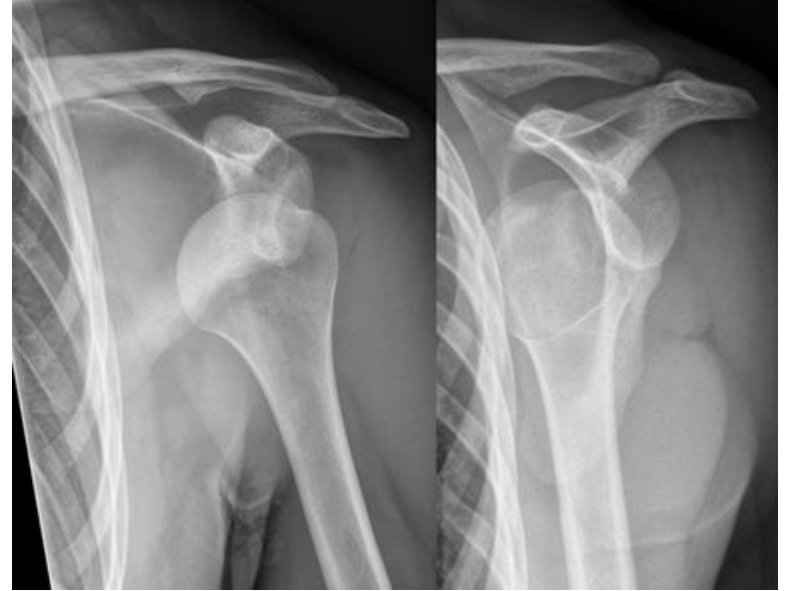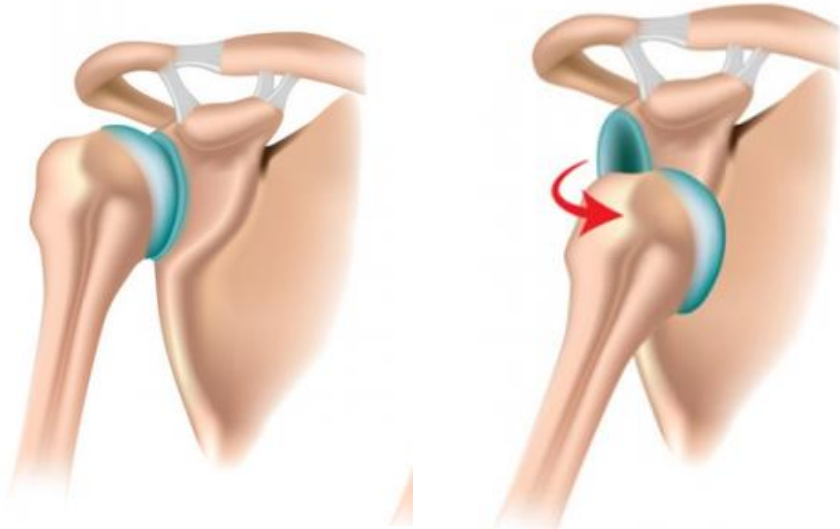
Bankart repair for traumatic anterior shoulder instability; is it still the golden standard?

Michel PJ van den Bekerom

Orthopaedic surgeon

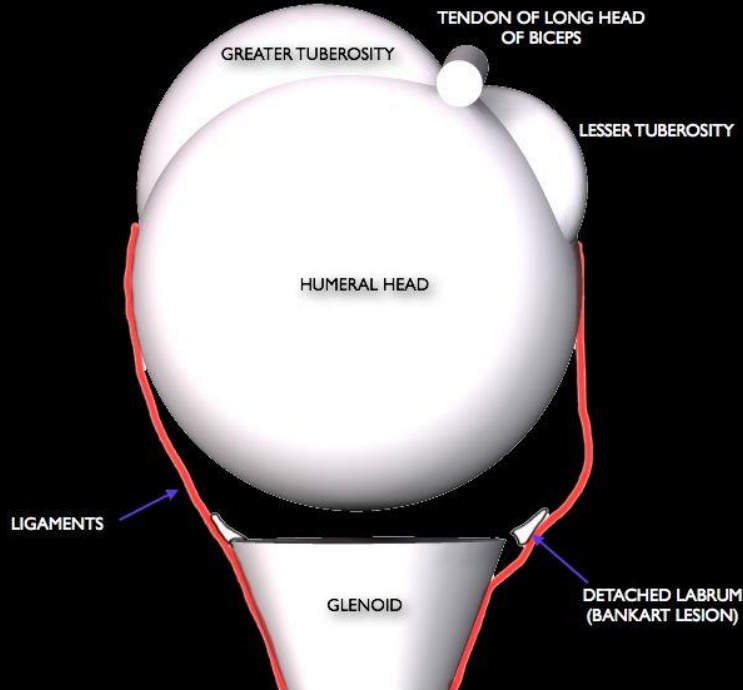


Shoulder dislocation

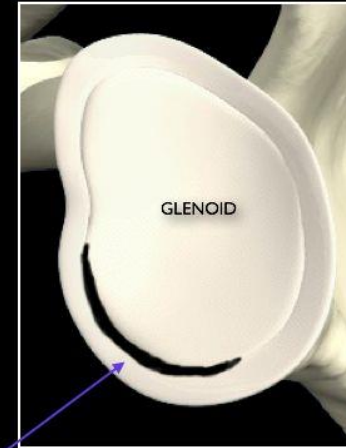


Bankart or labrum lesion

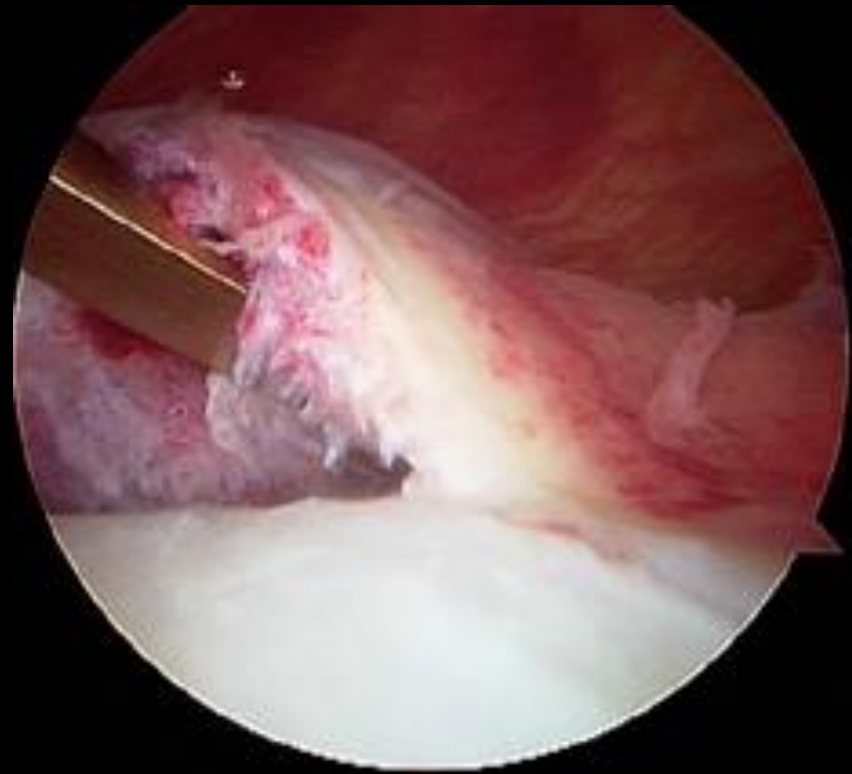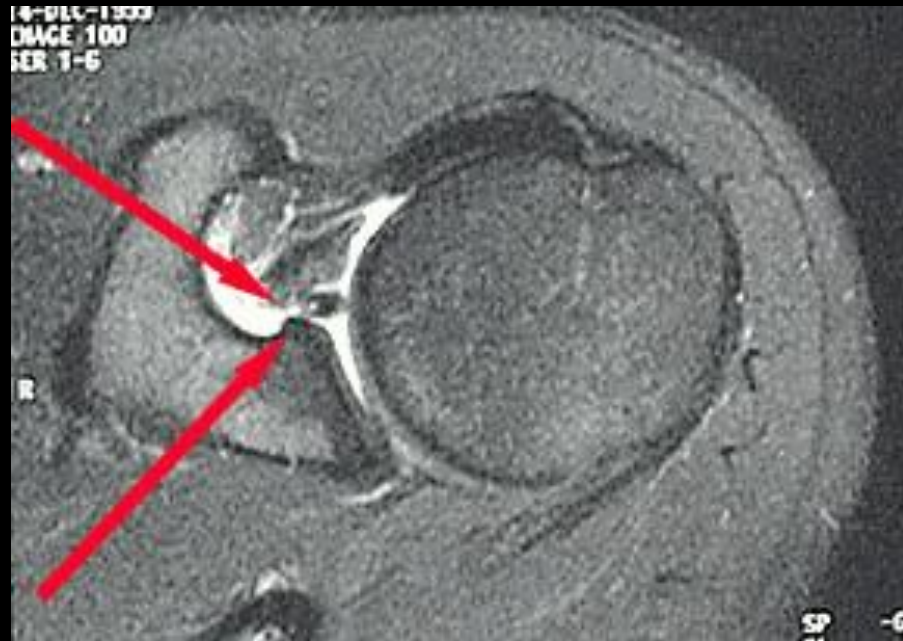
AXIAL
VIEW



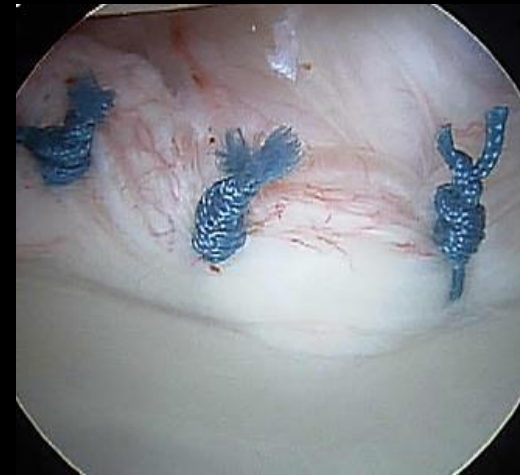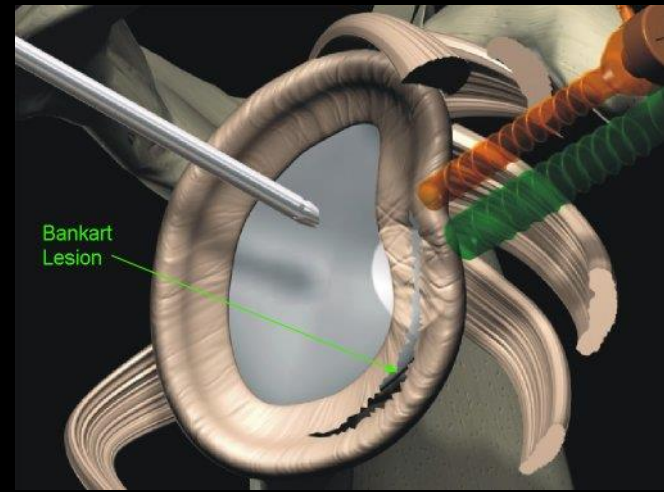
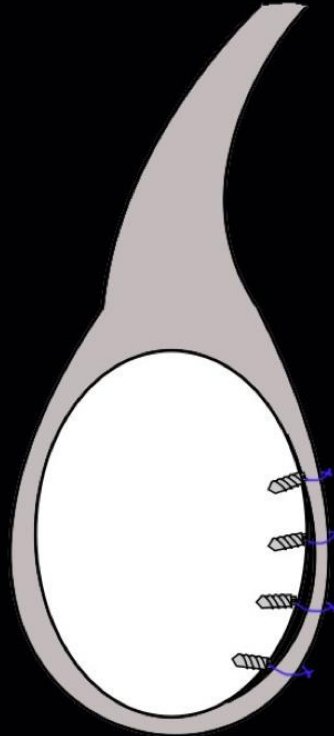
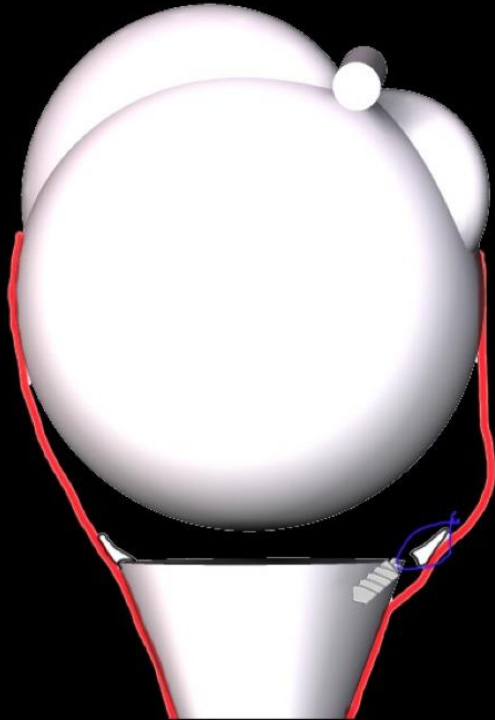
LATERAL
VIEW

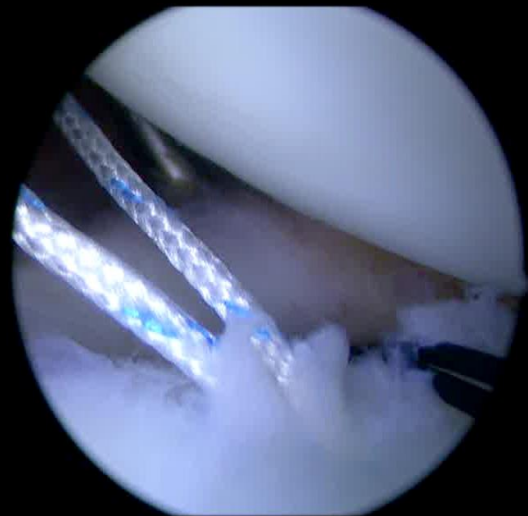
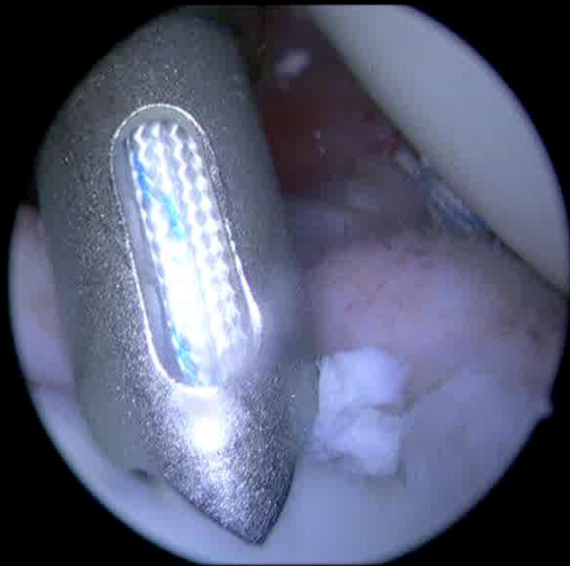
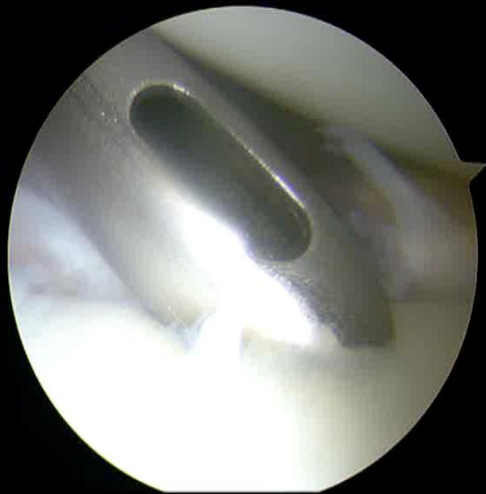
Labrum lesion



Arthroscopic Bankart repair





Long-term outcomes of the Bankart and Latarjet repairs: a systematic review

Twenty-eight studies with 1652 repairs at minimal 5 years FU were analyzed.

Re-dislocation rate

15% following arthroscopic Bankart repair

3% following Latarjet repair

Complication rates were

0% arthroscopic Bankart repair



9 % open Latarjet

high rates of post-operative subjective instability symptoms

High rates of radiographic arthritis

Recurrent instability

Recurrent Instability After Arthroscopic Bankart Reconstruction: A Systematic Review of Surgical Technical Factors

[Landon Brown](#), M.D., [Shane Rothermel](#), M.D., [Rajat Joshi](#), B.S., [Aman Dhawan](#), M.D.  
Penn State Milton S. Hershey Medical Center, Hershey, Pennsylvania, U.S.A.

Conclusions

Our systematic review reveals that despite individual study, and previous systematic reviews pointing to the contrary, the composite contemporary published literature would support no difference in the risk of recurrent instability after arthroscopic Bankart reconstruction with rotator interval closure, differing numbers of anchors used for the repair, use of knotless versus standard anchors, or use of bioabsorbable versus nonabsorbable anchors. We recommend surgeons focus on factors that have been shown to modify the risk factors after arthroscopic Bankart reconstruction, such as patient selection.

Recurrent instability

Balg JBJS Br 2007, Rouleau AJSM 2013,
Alkaduhini JSES 2016

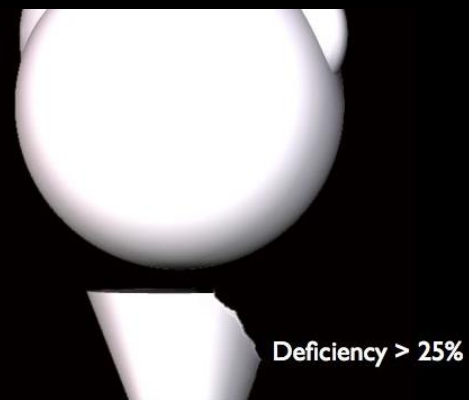
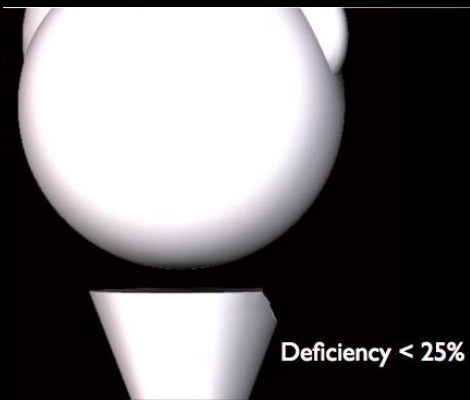
- patient age under 20 years
- competitive or contact sports or those involving forced overhead activity
- shoulder hyperlaxity

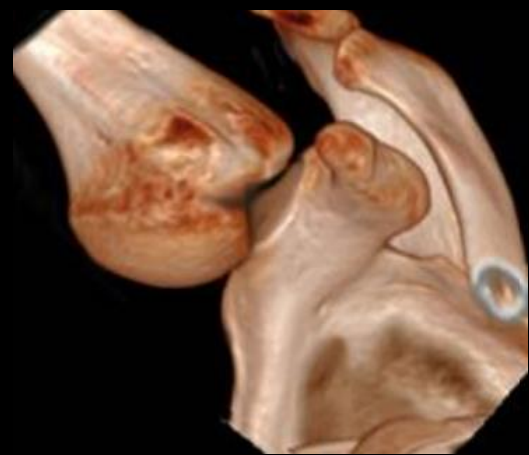
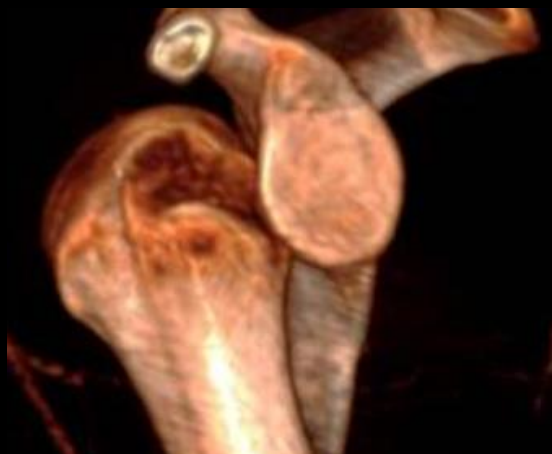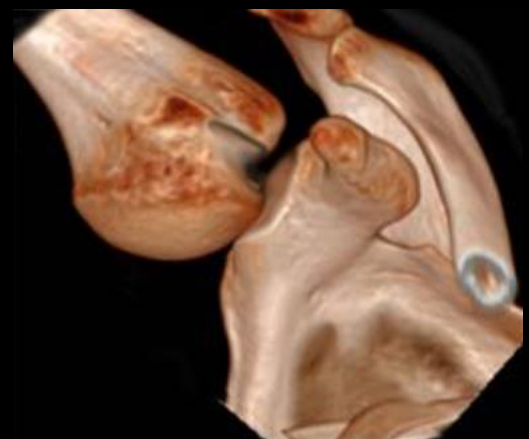
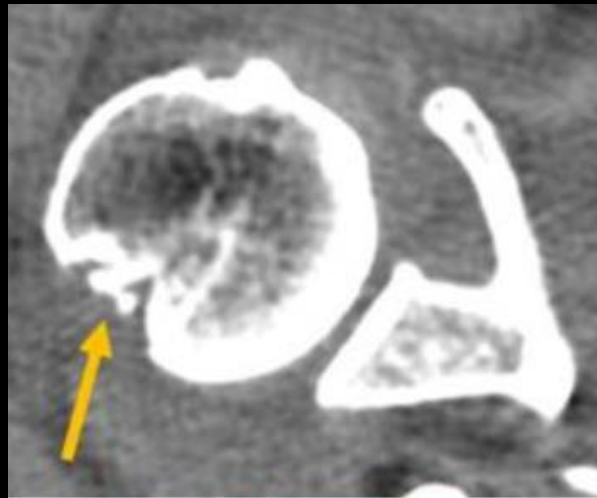
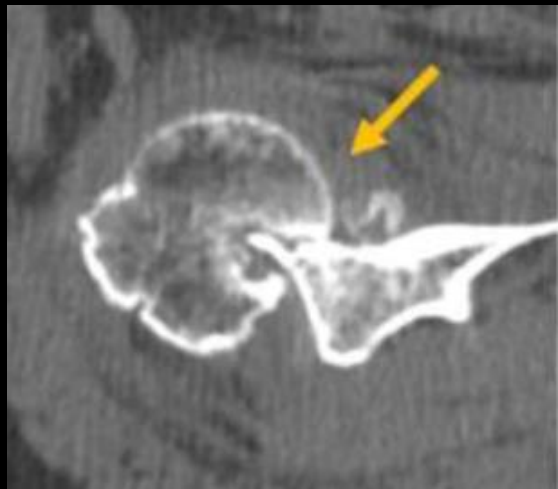- loss of the sclerotic inferior glenoid contour
- Hill-Sachs lesion present on an anteroposterior radiograph

- Glenoid version, inclination and curvature



- Brain?


Glenoid bone loss





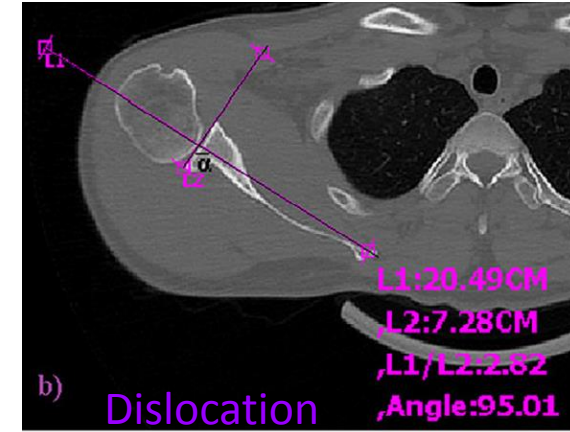
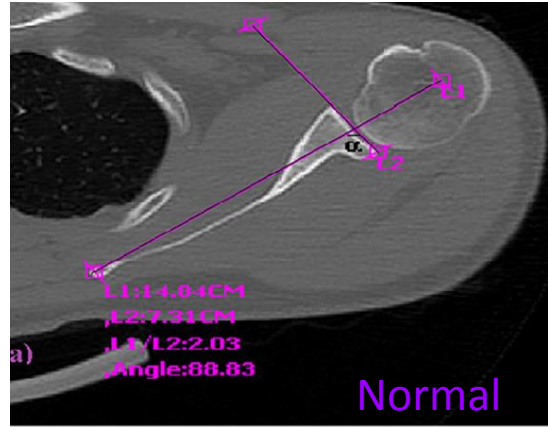
ENGAGING HILL SACHS



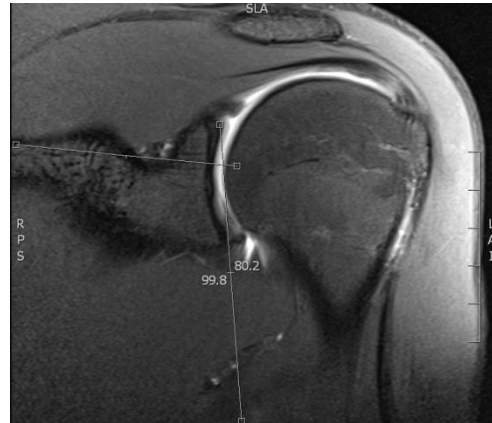


Glenoid morphology

Version



Inclination

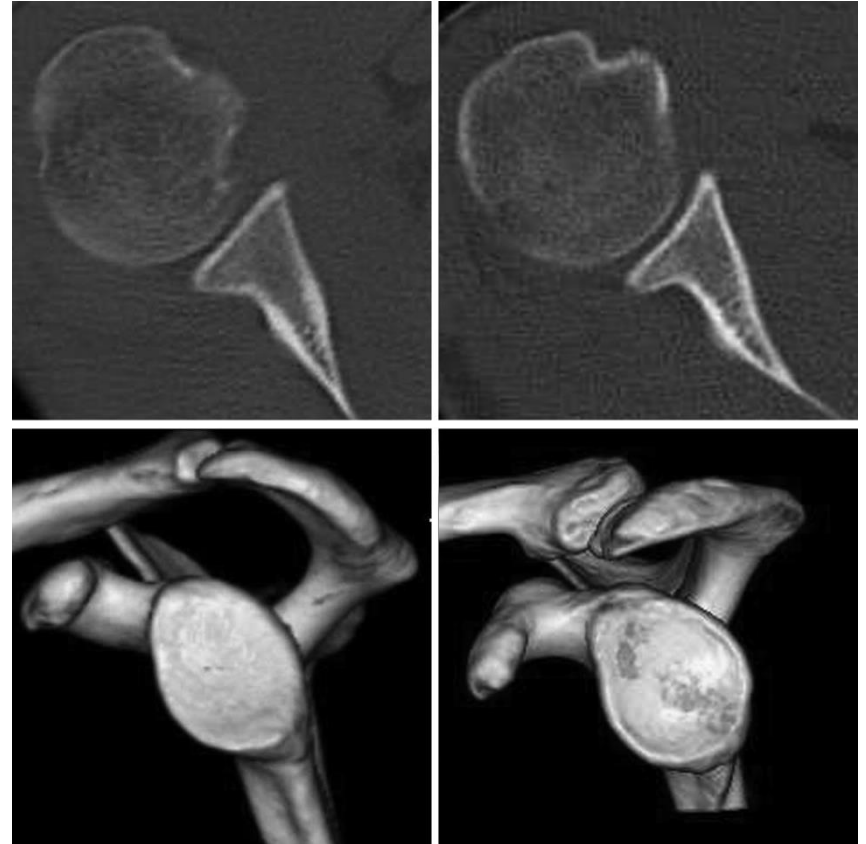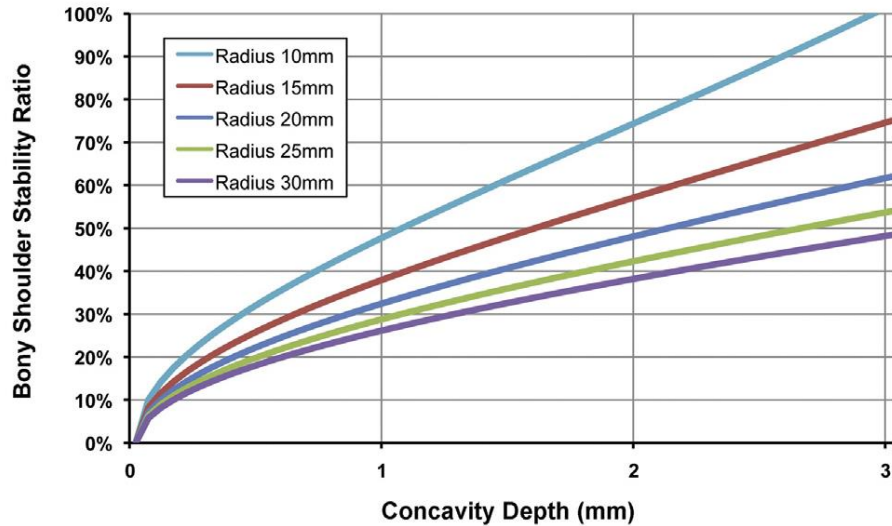


Aygun JSES 2016
Eichinger AJSM 2016
Hohmann JSES 2015
Peltzer JSES 2015

Glenoid morphology

Moroder Arthroscopy 2015

Curvature



In the brain?

Medicine & Science in Sports & Exercise. 47(12):2612–2620, DEC 2015

DOI: 10.1249/MSS.0000000000000726, PMID: 26110696

Issn Print: 0195-9131

Publication Date: 2015/12/01

[Share](#) [Print](#)

Neural Correlates of Clinical Scores in Patients with Anterior Shoulder Apprehension


GREGORY CUNNINGHAM; DAVIDE ZANCHI; KIRSTEN EMMERT; ROTEM KOPEL; DIMITRI VAN DE VILLE; ALEXANDRE LÄDERMANN; SVEN HALLER; PIERRE HOFFMEYER

Shoulder Apprehension Impacts Large-Scale Functional Brain Networks

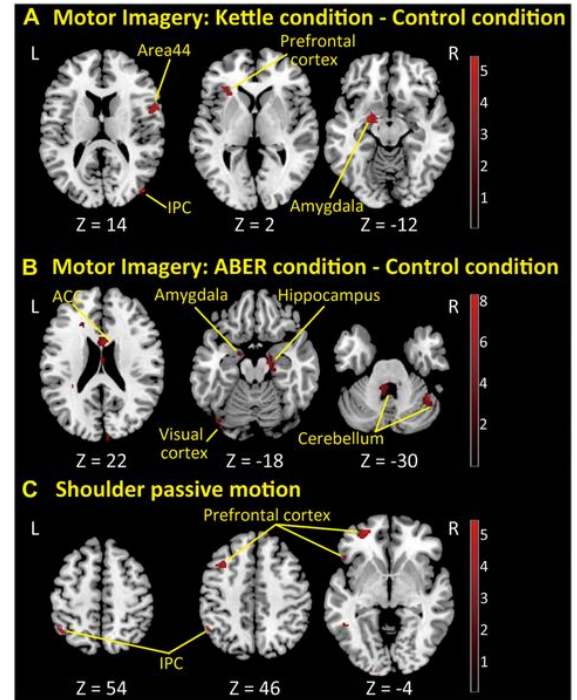
S. Haller, G. Cunningham, A. Laedermann, J. Hofmeister, D. Van De Ville, K.-O. Lovblad and P. Hoffmeyer

American Journal of Neuroradiology April 2014, 35 (4) 691-697; DOI: <https://doi.org/10.3174/ajnr.A3738>

The Neural Correlates of Shoulder Apprehension: A Functional MRI Study

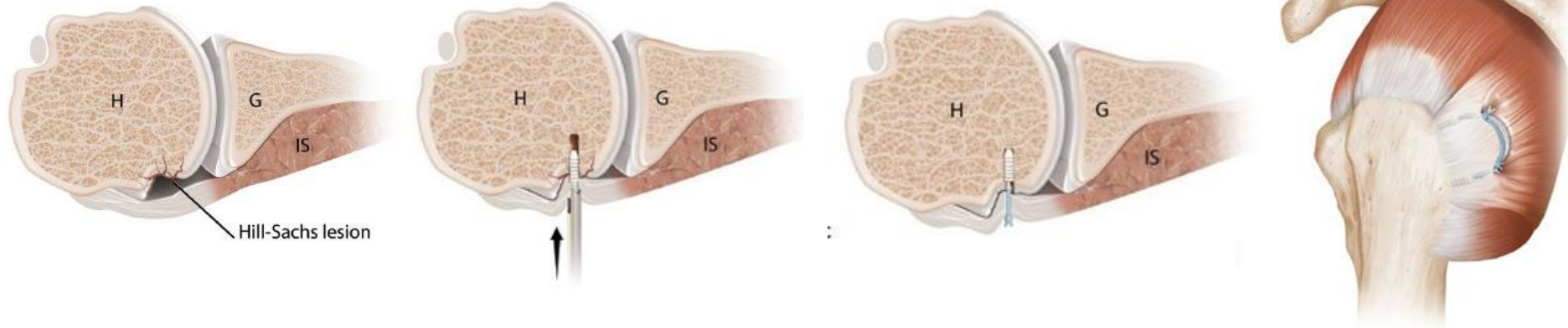
Hitoshi Shitara , Daisuke Shimoyama, Tsuyoshi Sasaki, Noritaka Hamano, Tsuyoshi Ichinose, Atsushi Yamamoto, Tsutomu Kobayashi, Toshihisa Osawa, Haku Iizuka, Takashi Hanakawa, Yoshito Tsushima, Kenji Takagishi

Published: September 9, 2015 • <https://doi.org/10.1371/journal.pone.0137387>

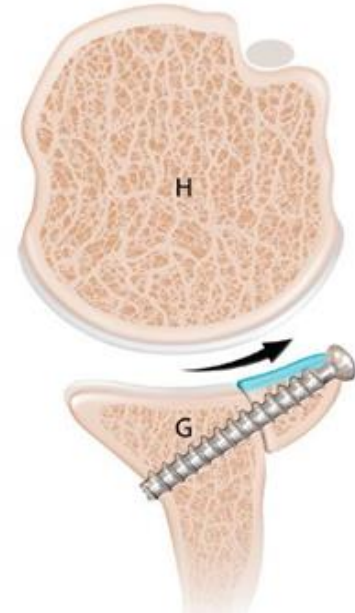
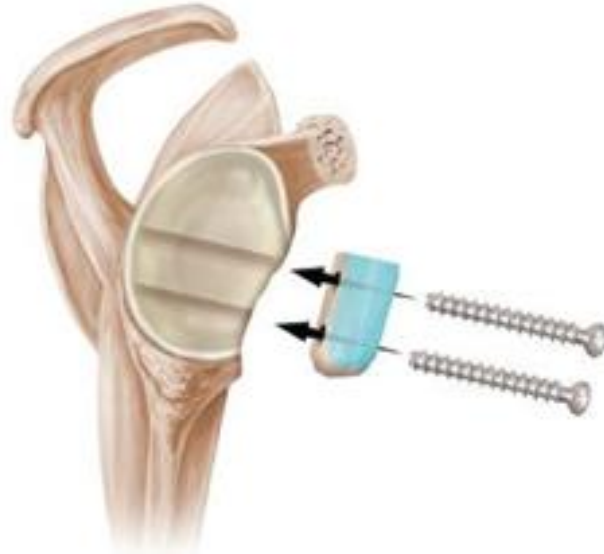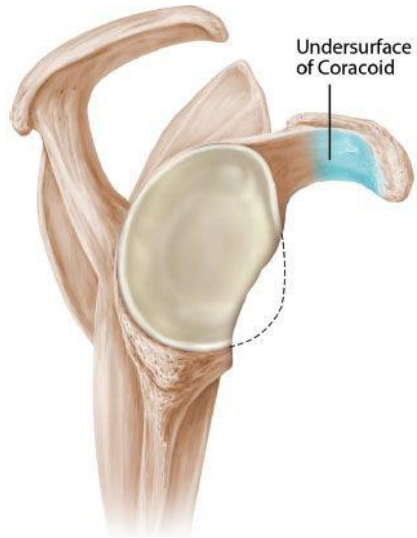


Remplissage

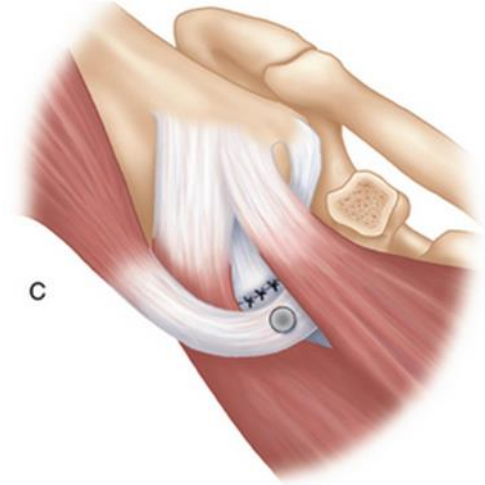
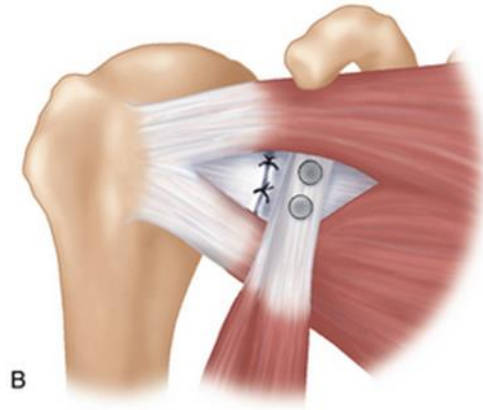
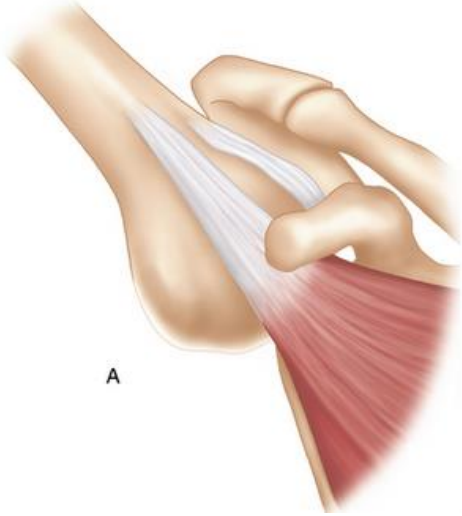
additional remplissage resulted in less instability (1.8% versus 18.3%; $p < 0.001$; relative risk ratio: 10.2) and higher Rowe scores (90 versus 81 points; $p < 0.001$).



Latarjet procedure



Latarjet procedure



Conclusion

Arthroscopic Bankert repair has a substantial chance of recurrent instability but low complication rate

Hill Sachs: remplissage

Chance of recurrent dislocation too high: Latarjet procedure

**Bankart repair is still first choice
in operative treatment of traumatic
anterior shoulder instability.**



Shoulder
ElbowUnit
OLVG

