

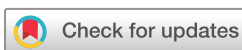# BMJ Open Direct active rehabilitation after reverse total shoulder arthroplasty: an international multicentre prospective cohort safety study with 1-year follow up

Anke Kornuijt <sup>1</sup>, Lieke de Vries <sup>2</sup>, Walter van der Weegen,<sup>1</sup> Robert Jan Hillen,<sup>2</sup> Rob Bogie,<sup>1</sup> Remco Stokman,<sup>3</sup> Derk van Kampen<sup>2</sup>

**To cite:** Kornuijt A, de Vries L, van der Weegen W, *et al*. Direct active rehabilitation after reverse total shoulder arthroplasty: an international multicentre prospective cohort safety study with 1-year follow up. *BMJ Open* 2023;**13**:e070934. doi:10.1136/bmjopen-2022-070934

► Prepublication history and additional supplemental material for this paper are available online. To view these files, please visit the journal online (<http://dx.doi.org/10.1136/bmjopen-2022-070934>).

Received 13 December 2022  
Accepted 27 March 2023



© Author(s) (or their employer(s)) 2023. Re-use permitted under CC BY-NC. No commercial re-use. See rights and permissions. Published by BMJ.

<sup>1</sup>Sports and Orthopedics Research Centre, Anna Hospital, Geldrop, the Netherlands

<sup>2</sup>Orthopedic Surgery, Dijklander Hospital, Hoorn/Purmerend, the Netherlands

<sup>3</sup>Orthopedic Surgery, Curaçao Medical Center, Willemstad, Curaçao

## Correspondence to

Anke Kornuijt;  
A.Kornuijt@st-anna.nl

## ABSTRACT

**Objectives** To gain insight in the safety of direct active rehabilitation without immobilisation in patients undergoing reverse total shoulder arthroplasty without subscapularis reattachment, measured by the occurrence of complications until 1-year follow up. Next, to explore improvement in shoulder function and in patient-reported outcome measures.

**Design** An international multicentre prospective cohort safety study.

**Setting** Patients indicated for reverse total shoulder arthroplasty, visiting the orthopaedics outpatient clinic at two hospitals in the Netherlands and one hospital in Curaçao between January 2019 and July 2021, were selected.

**Participants** 100 patients (68% female, mean age 74±7.0 years) undergoing unilateral primary shoulder replacement were included if: ≥50 years, diagnosed with shoulder osteoarthritis, rotator cuff arthropathy or avascular necrosis, and selected for reverse total shoulder arthroplasty. A sling was used for only 1 day, followed by a progressive active rehabilitation for ≥12 weeks with no precautions.

**Main outcome measures** Complications, range of motion and patient-reported outcome measures (Oxford Shoulder Score, Pain Numeric Rating Scale and EuroQoL-5D for quality of life). Patients were evaluated preoperatively and 6 weeks, 3 months and 1 year postoperatively.

**Results** In total, 17 complications were registered (17.0%) including five (5.0%) categorised as potentially related to the rehabilitation strategy: one dislocation, one acromion fracture and three cases with persistent pain. Anteflexion, abduction and external rotation, pain scores and the Oxford Shoulder Score all improved significantly ( $p<0.05$ ) at all time points compared with preoperative. Quality of life improved significantly from 3 months onwards. These secondary outcomes improved further until 1 year postoperatively.

**Conclusion** Direct active rehabilitation after reverse total shoulder arthroplasty seems to be safe and effective. Potentially, this approach will lead to less dependent patients and faster recovery. Larger studies, preferably including a control group, should corroborate our results.

## STRENGTHS AND LIMITATIONS OF THIS STUDY

- ⇒ The strength of our study is the international design with multiple surgeons and two different types of modern shoulder prosthesis, therefore representing a broad range of patients.
- ⇒ Furthermore, we accounted for confounding factors (age, sex and type of prosthesis) in the statistical analysis.
- ⇒ The main limitation of this study is the lack of a control group, besides results from previous literature.
- ⇒ In addition, the sample size was relatively small ( $n=100$ ).

**Trial registration number** NL7656.

## INTRODUCTION

Despite the gained popularity of reverse total shoulder arthroplasty (rTSA), there is a high level of heterogeneity in the published rehabilitation guidelines post rTSA. The only consensus is that physical therapy is considered essential in optimising patient outcomes and that patients might benefit from deltoid and scapulothoracic rehabilitation after rTSA.<sup>1,2</sup>

Traditionally, patients undergoing rTSA surgery are immobilised for at least 2–6 weeks to protect the operated joint and to allow tissue healing, as described by Bullock *et al*.<sup>1</sup> In the early days, the subscapularis tendon was detached during surgery and reattached to the tuberculum minus, and consequently needed time to heal. In modern rTSA surgery, reattaching the subscapularis tendon is not mandatory as presented by Friedman *et al*.<sup>3</sup> and Vourazeris *et al*.<sup>4</sup> Both studies showed similar outcomes and complication rates after shoulder arthroplasty with or without reattaching the tendon.<sup>3,4</sup> Also, de Boer *et*

*ab* showed no significant differences in range of motion (ROM) between reattaching the subscapularis tendon or resection. Without the need to reattach the subscapularis tendon, combined with the stability provided by the modern design of rTSA, nowadays patients should be able to start mobilisation directly postoperatively.

Direct active use of the new shoulder joint could potentially lead to improved ROM on the short term and better motor control of the deltoid muscle at an earlier stage. In addition, patients might resume activities faster if no immobilisation is applied. This faster independency could result in psychological and emotional advantages for patients.<sup>6</sup> Furthermore, prolonged immobilisation of the arm can be disabling, especially in the elderly population, resulting in increased incidence of falling.<sup>6</sup> On the contrary, it is unknown if early, unrestricted motion leads to an increased dislocation rate, pain or readmissions.<sup>7</sup>

There are a limited number of studies evaluating early active rehabilitation after rTSA.<sup>6–8</sup> These suggest that an early start with exercising could result in improved function with low complication rates; however, in all a period of immobilisation is still applied by wearing a sling, and/or precautions are prescribed.<sup>6–8</sup> In contrast to these studies, this current study was less conservative and applied an active rehabilitation protocol starting on postoperative day 1, with no immobilisation of the shoulder joint and without any precautions. We hypothesised that this approach would not result in more complications and would lead to early improvements of functional outcomes related to direct rehabilitation. Therefore, the primary objective of this study was to gain insight in the safety of direct active rehabilitation without immobilisation in patients undergoing rTSA without subscapularis reattachment, measured by the occurrence of complications until 1-year follow up. Second, this study explored the improvement in shoulder function (ROM) and in patient-reported outcome measures (PROMs).

## METHODS

This study was an international multicentre prospective cohort safety study.<sup>9</sup> The study was reported according to the Strengthening the Reporting of Observational Studies in Epidemiology (STROBE) statement.<sup>10</sup> All patients 50 years and older with an indication for rTSA surgery, visiting the orthopaedics outpatient clinic at Dijklander Hospital (Hoorn/Purmerend, the Netherlands), Anna Hospital (Geldrop, the Netherlands) or Curaçao Medical Center (Willemstad, Curaçao) between January 2019 and July 2021 were selected if they met the inclusion criteria. The indication for surgery was shoulder complaints based on shoulder osteoarthritis, rotator cuff arthropathy or avascular necrosis. Exclusion criteria were: (1) unable to complete the rehabilitation protocol; (2) unable to complete the questionnaire(s) or (3) acute fracture treatment. After obtaining written informed consent, patient demographics were collected as well as shoulder function and PROMs.

Patients from Dijklander Hospital received an Equinox rTSA shoulder prosthesis (Exactech, Gainesville, Florida, USA). Patients from Anna Hospital and Curaçao Medical Center received a Comprehensive Total Shoulder prosthesis (Zimmer Biomet, Warsaw, Indiana, USA). During admission, patients received standardised care according to local protocols. The surgical procedure was described in the study protocol of van Essen *et al.*<sup>9</sup> In summary, all procedures were done with the patient in the beach chair position using a deltopectoral approach, without reattachment of the subscapularis tendon. All patients received an ultrasound-guided interscalene regional block with a maximum of 20 mL levobupivacaine 0.5% (5 mg/mL) combined with general anaesthesia. No drains or peripheral pain catheters were used. The day after surgery, active use of the shoulder started following a strict physical therapy protocol without the use of a sling for immobilisation. The rehabilitation took into account the unique biomechanical changes that occur after rTSA. Deltoid functioning is affected favourably by the design of the reverse prosthesis, which medialises the centre of rotation and distalises the humerus, allowing the deltoid muscle to partially replace the function of the rotator cuff muscles.<sup>11</sup> Furthermore, periscapular muscles play an important role due to increased scapulothoracic motion during elevation.<sup>12</sup> Therapy gradually progressed and concerned improving ROM and strengthening of the deltoid muscle,<sup>13</sup> of the periscapular muscles and of remaining cuff muscles. High number of repetitions with low weights was preferred to enhance shoulder muscle endurance.<sup>14</sup> Normal use of the arm and shoulder was encouraged for all activities, with no precautions. The active rehabilitation protocol is described in detail in the online supplemental appendix.

The effect of this direct mobilisation was evaluated at 6 weeks, 3 months and 1 year postoperatively. Complications and re-admissions were recorded at all follow up moments. Complications were classified as potentially related to the rehabilitation strategy (eg, acromial/scapular spine stress fractures, shoulder dislocation)<sup>15</sup> or as other intraoperative and postoperative complications related to surgery (eg, infection, nerve problems, haematoma). Furthermore, the following PROMs were completed by the patients: (1) the validated Dutch version of the Oxford Shoulder Score (OSS), a 12-item questionnaire regarding pain and function of the shoulder (scores range from 0 to 48), with higher scores indicating better shoulder function and less pain;<sup>16 17</sup> (2) EuroQol-5 Dimensions-3 Levels (EQ-5D-3L), a health-related quality of life measure with a self-rating of health status (range 0–100, 100 is the best imaginable health status)<sup>18</sup> and (3) Numeric Pain Rating Scale (NPRS) in rest and in motion (range 0–10, 10 means the worst possible pain).<sup>19</sup> In addition, active range of motion of the shoulder was registered at the outpatient clinic by the orthopaedic surgeon or a trained orthopaedic resident. Anteflexion, abduction and external rotation with the arm at the side and 90° elbow flexion were expressed in degrees. Internal

rotation was classified using the Constant-Murley scoring method by recording the highest anatomic landmark the patient's thumb was able to reach, namely: dorsum of hand to lateral thigh, to buttock, to lumbosacral junction, to waist/3rd lumbar vertebra, to 12th dorsal vertebra or to interscapular region.<sup>20</sup> During outpatient clinical visits (at 2 weeks postoperatively for wound control and at all study follow up evaluations), patient compliance with the rehabilitation protocol was monitored.

A power analysis (significance level of 0.05 and a power of 0.90) suggested that >1300 patients with an rTSA would be required for sufficient statistical power to test whether the rate of complications (approximately 15%)<sup>21</sup> would be the same between the former rehabilitation strategy with immobilisation of the shoulder for several weeks and the direct active rehabilitation (maximum allowed difference 3%). Since this would put a large number of patients at risk, we first designed this safety study to gain insight in the risk of complications of direct active rehabilitation without immobilisation in patients undergoing rTSA.

Descriptive statistics were used for baseline participant characteristics and to evaluate primary (complications) and secondary (ROM and PROMs) study outcomes. Categorical variables are presented as numbers and proportions. For continuous variables, normality was assessed visually (eg, histograms, boxplots) and through the Shapiro-Wilk test. Normally distributed data are presented as mean±SD, while median and IQR were used for non-parametric data.<sup>22</sup> Patients with complications were compared with patients without complications regarding differences in age, sex and type of rTSA. Age was analysed using the independent samples t-test. Sex and prosthesis type were evaluated with  $\chi^2$  to assess for differences between groups and Fisher's exact test when expected counts were less than 5. Whether secondary outcomes improved postoperatively compared with preoperative values was tested using a linear mixed model analysis, an approach robust to missing data.<sup>23</sup> ROM and PROMs were analysed at all time points as dependent variables. Sex and type of rTSA were entered as independent factors, and age was added in the model as covariate. Intention to treat analysis was applied, since patients with complications were included in the analysis. A p value<0.05 was considered statistically significant. Statistical analysis was performed using the Statistical Package for the Social Sciences (V.28.0; IBM, SPSS). Finally, adherence with the rehabilitation protocol was also assessed by reviewing the patient's physical therapy record in a 10% sample.

### Patient and public involvement

No patients were involved.

## RESULTS

All patients that met the inclusion criteria participated in the study, which comprised a total of 100 patients undergoing primary unilateral rTSA. Mean age at the time of

**Table 1** Characteristics of study participants

Participant characteristics	Outcome
Age at surgery in years, mean±SD	74±7.0
Female, n (%)	68 (68)
Diagnosis, n (%)	
Osteoarthritis	50 (50.0)
Cuff arthropathy	36 (36.0)
Both osteoarthritis and cuff arthropathy	13 (13.0)
Avascular necrosis	1 (1.0)
Type of shoulder prosthesis, n (%)	
Equinoxe reverse system	55 (55.0)
Comprehensive total shoulder system	45 (45.0)
n, number.	

surgery was 74±7.0 years and 68% of the patients were female (table 1).

In total, 17 complications were registered (17.0%) in 14 patients during the first postoperative year (table 2). All patients were seen 1 year postoperatively, except for two

**Table 2** Complications during the first postoperative year

Total complications, n (%)	17 (17.0)
<b>Complications potentially related to the rehabilitation strategy, n (%)</b>	<b>5 (5.0)</b>
At 6 weeks FU	
Persistent pain which needed additional non-surgical treatment	3
At 3 months FU	
Acromial fracture (without trauma)	1
Shoulder dislocation	1
<b>Other complications, n (%)</b>	<b>12 (12.0)</b>
During the procedure and hospital admission	
Skin injury lower arm	1
Death post surgery due to ventricular fibrillation	1
Bladder retention	1
At 6 weeks FU	
Temporary plexus neuropraxia	1
Periprosthetic fracture (fall)	1
Ribfracture (fall)	1
Scapula fracture (fall)	1
Dislocated total hip (fall)	1
At 3 months FU	
Infection	1
Acromial fracture (fall)	1
At 1 year FU	
Scapula notching on X-ray without clinical symptoms	1
Death	1
FU, follow up; n, number.	



patients who died (one immediately after surgery, one 8 months postoperatively). Five complications (5.0%) were categorised as potentially related to the rehabilitation strategy, all occurring during the first 3 months. Looking more closely at these five patients, one patient presented at the outpatient clinic 8 weeks after surgery with acute shoulder pain without trauma. A CT scan confirmed an acromion fracture for which 4 weeks immobilisation was advised. Only one patient experienced dislocation of the shoulder prosthesis which occurred 2 months postoperatively. This was successfully treated by closed reduction in the operating room and restricted ROM for 6 weeks. A full recovery was reached after 1 year. Three patients experienced persistent pain for which a consult with the pain specialist was scheduled for two patients, and one patient was treated with dry needling by the physical therapist. There were 12 other complications (12.0%), including five which were caused by a fall. One patient was diagnosed with a deep wound infection 10 weeks after surgery, treated with two-stage revision. Patients with complications were not statistically different from patients without complications regarding age (76.1±8.9 years vs 73.9±6.6 years, respectively,  $p=0.285$ ), sex (10.3% female and 21.9% male in the group with complications, Fisher's exact test  $p=0.133$ ) and type of rTSA (20.0% Comprehensive Total Shoulder and 13.8% Equinox shoulder prosthesis in the group with complications, Pearson  $\chi^2$   $p=0.708$ ).

ROM and PROMs results during the first postoperative year are presented in table 3. Anteflexion, abduction and external rotation improved significantly at all time points compared with preoperative, independent of age, sex and

type of prosthesis ( $p<0.05$ , figure 1). Similar results are shown for the pain scores (NPRS) and OSS, while quality of life (EQ-5D-3L) improved significantly at 3 months and 1 year compared with preoperative. The improvement in internal rotation postoperatively is presented in figure 2. Ten patient records (10%) were retrospectively studied to check how thorough therapists followed the rehabilitation guidelines. All showed good compliance with the prescribed protocol.

## DISCUSSION

This study aimed to gain insight in the safety of an active rehabilitation protocol without immobilisation and starting directly after rTSA surgery. Main results showed a total complication rate of 17.0% ( $n=17$ ) during the first postoperative year. Only five complications (5.0%) were potentially related to the rehabilitation strategy: one dislocation, one acromion fracture and three cases with persistent pain, all of which occurred on the short term ( $\leq 3$  months). This indicates, in this relatively small group of patients, that direct active rehabilitation and no immobilisation appear to be safe. Anteflexion, abduction and external rotation, pain scores and the OSS all improved significantly from 6 weeks onwards.

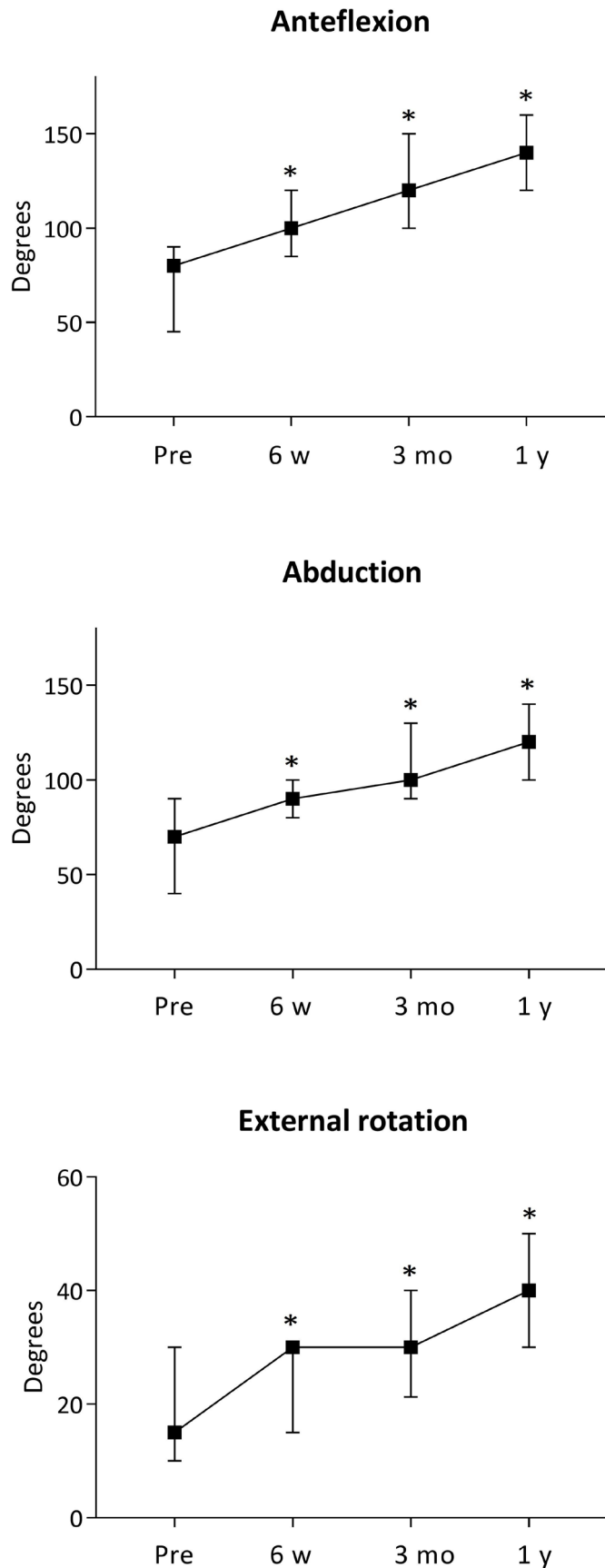
The three types of complications potentially related to the rehabilitation strategy in this study are among the top three complications for an rTSA.<sup>24</sup> The complication rates of instability (1.0%,  $n=1$ ), acromial fracture (1.0%,  $n=1$ ) and pain complaints (3.0%,  $n=3$ ) are comparable to the recent study of Parada *et al*<sup>24</sup> in >4000 patients with an rTSA. Although the biggest concern of early

**Table 3** Range of motion and results of patient-reported outcome measures

Outcome	Preoperative	Six weeks postoperative	Three months postoperative	One year postoperative
Anteflexion (degrees), median (IQR)	80 (45–90)	100 (85–120)	120 (100–150)	140 (120–160)
Abduction (degrees), median (IQR)	70 (40–90)	90 (80–100)	100 (90–130)	120 (100–140)
External rotation (degrees), median (IQR)	15 (10–30)	30 (15–30)	30 (21–40)	40 (30–50)
Internal rotation (category*), %				
0	19.6	7.9	2.3	1.1
1	49.5	73.0	62.1	42.7
2	15.5	16.9	28.7	34.8
3	7.2	1.1	3.4	9.0
4	7.2	1.1	3.4	10.1
5	1.0	0.0	0.0	2.2
NPRS in rest (0–10), median (IQR)	7 (5–8)	3 (1–4)	1 (0–3)	1 (0–2)
NPRS in motion (0–10), median (IQR)	8 (8–9)	4 (2–6)	2 (1–4)	2 (0–5)
OSS (0–48), median (IQR)	19 (12–24)	26 (19–33)	36 (28–40)	40 (33–44)
EQ-5D self-rating of health status (0–100), median (IQR)	70 (50–80)	71 (60–80)	80 (62–90)	80 (70–90)

\*Constant-Murley scoring method,<sup>20</sup> category 0=lateral thigh; 1=buttock; 2=lumbosacral junction; 3=waist/3rd lumbar vertebra; 4=12th dorsal vertebra; 5=interscapular region.  
EQ-5D, EuroQol-5 Dimensions; NPRS, Numeric Pain Rating Scale; OSS, Oxford Shoulder Score.





**Figure 1** Median (IQR) anteflexion, abduction and external rotation range of motion during the first postoperative year. \*Significant difference ( $p < 0.05$ ) compared with preoperative value. mo, months; pre, preoperative; w, weeks; y, year.

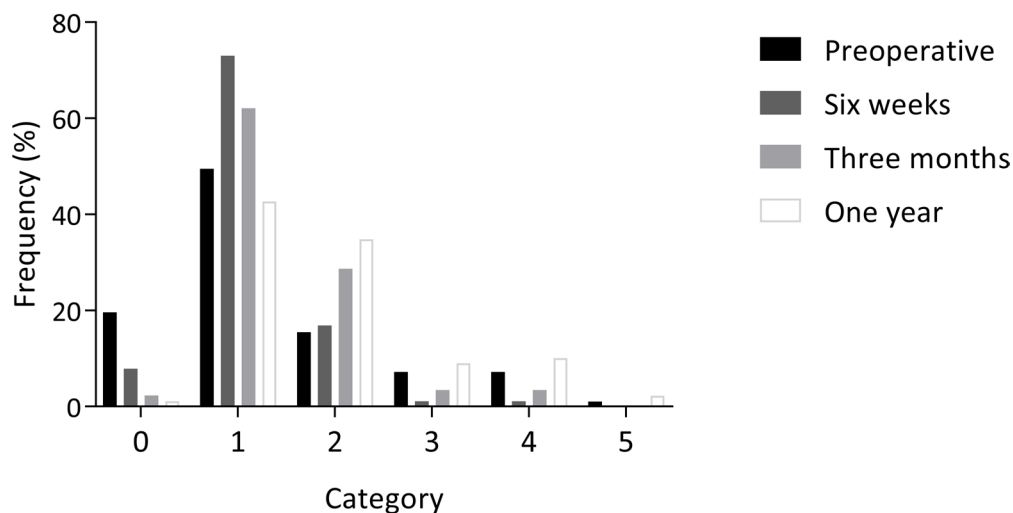
rehabilitation is dislocation of the shoulder arthroplasty, in our study only one patient (1.0%) experienced a dislocation, 2 months after surgery. Regarding other complications, we included all adverse events that occurred (both complications and problems, defined by Ascione *et al*<sup>25</sup>), resulting in 11 different complications. Remarkable is the high rate of patients who experienced a fall during the first 3 months ( $n=5$ , 5.0%), resulting in varying fractures ( $n=4$ ) or total hip dislocation ( $n=1$ ). We assumed that without a sling, patients would have better proprioception and therefore less tendency to fall, as was reported in the study of Lee *et al*.<sup>6</sup> The high number of falls may also be a reflection of the (older) patient population eligible for rTSA. In this study, the mean age of patients was  $74 \pm 7.0$  years.

Compared with traditional immobilisation, we expect the biggest advantage of early rehabilitation in the first few weeks. This was demonstrated by significant improvements of ROM, NPRS and OSS already at 6 weeks after surgery and quality of life at 3 months. The improvements of secondary outcomes continued even further until 1-year follow up. In addition, these gains in shoulder function and PROMs at 6 weeks represent clinically relevant changes.<sup>26 27</sup> Furthermore, no need for shoulder immobilisation in the first few weeks after surgery may decrease the inconvenience caused by mandatory sling use and may result in less dependency on additional care. This will potentially reduce healthcare costs.

The effect of early active rehabilitation after rTSA was previously evaluated in a limited number of studies. Hagen *et al*<sup>7</sup> found no difference in ROM and complication rates between early mobilisation ( $n=42$ ) and delayed therapy ( $n=44$ ). Contrary to our study results at 6 weeks, both rehabilitation groups showed no significant improvements in anteflexion and abduction, and even a decline in external rotation.<sup>7</sup> A second study concluded that early active rehabilitation targeting the deltoid and the external rotator muscles ( $n=30$ ) is safe (no complications) and effective and may have early clinical benefits over a delayed active rehabilitation programme ( $n=33$ ).<sup>8</sup> In both randomised controlled trials, both treatment groups had to wear a sling for 6 weeks.<sup>7 8</sup> In our study, we used a more aggressive mobilisation protocol starting on day 1 postoperatively, with no use of a sling. A third study by Lee *et al*<sup>6</sup> compared three groups: (1) 6 weeks' immobilisation in a sling ( $n=114$ ); (2) 3 weeks' immobilisation ( $n=125$ ) and (3) accelerated rehabilitation without immobilisation ( $n=118$ ) in patients after rTSA. They demonstrated that accelerated rehabilitation is effective and safe with low complication rates.<sup>6</sup> In accordance with our study, they recommend a comparable accelerated rehabilitation regime without immobilisation.

The strength of our study is the international design with multiple surgeons and two different types of modern shoulder prosthesis. These results are therefore representative for a broader range of patients. In addition, we accounted for confounding factors (age, sex and type of prosthesis) in our statistical analysis. The main limitation

## Internal rotation



**Figure 2** Internal rotation range of motion during the first postoperative year. Constant-Murley scoring method, category 0=lateral thigh; 1=buttock; 2=lumbosacral junction; 3=waist/3rd lumbar vertebra; 4=12th dorsal vertebra; 5=interscapular region.

of our study is the lack of a control group, besides results from previous literature.<sup>6-8</sup> Another limitation is the small sample size (n=100). Furthermore, all patients were treated by their local physical therapist. While leaving room for treatment variation, this closely reflects normal clinical practice. Rehabilitation guideline adherence was reinforced at each postoperative hospital visit and the physical therapy records check (n=10) showed good compliance. Finally, we have no results beyond 1-year follow up, including long-term information on aseptic loosening and any revision surgery for this reason. Since the implementation of a rapid recovery programme after hip and knee arthroplasty did not lead to increased aseptic loosening, we do not expect different results after shoulder arthroplasty.<sup>28</sup>

## CONCLUSION

This study indicates that direct active rehabilitation after rTSA without immobilisation of the shoulder joint seems to be safe and effective. After 1-year follow up, 17 complications were registered (17.0%) including 5 (5.0%) categorised as potentially related to the rehabilitation strategy. Although a control group was lacking in this study, our complication rate matches complication rates in recent literature. Anteflexion, abduction and external rotation, pain scores and the OSS were significantly, and clinically relevant, improved from 6 weeks onwards. A direct active rehabilitation after rTSA can be done safely and will potentially lead to less dependent patients and a faster recovery. Larger studies, preferably including a control group, should corroborate our results.

**Contributors** AK, LdV, WvdW, RB and DvK: study concept and design; AK and DvK: design physical therapy protocol; RJH, RB, RS and DvK: study inclusion and surgery; AK, LdV, WvdW, RJH, RB, RS and DvK: acquisition of data; AK, LdV, WvdW and DvK: data analysis and interpretation. AK, LdV and WvdW: manuscript preparation; AK,

LdV, WvdW, RJH, RB, RS and DvK: critical revision of the manuscript for important intellectual content and approval of final version; AK: author acting as guarantor.

**Funding** The authors have not declared a specific grant for this research from any funding agency in the public, commercial or not-for-profit sectors.

**Competing interests** The authors declared the following potential conflicts of interest with respect to the research, authorship and/or publication of this article: DvK and RJH have a consultancy contract with Exactech Company. This study was not sponsored by Exactech. All other authors declare that they have no competing interests.

**Patient and public involvement** Patients and/or the public were not involved in the design, or conduct, or reporting, or dissemination plans of this research.

**Patient consent for publication** Consent obtained directly from patient(s).

**Ethics approval** This study involves human participants but the Medical Ethics Committee from the VUmc and Curaçao reviewed this study and granted exemption from ethical approval (METC VUmc 2019.111, Curaçao 2019-02). Participants gave informed consent to participate in the study before taking part.

**Provenance and peer review** Not commissioned; externally peer reviewed.

**Data availability statement** All data relevant to the study are included in the article or uploaded as supplementary information.

**Supplemental material** This content has been supplied by the author(s). It has not been vetted by BMJ Publishing Group Limited (BMJ) and may not have been peer-reviewed. Any opinions or recommendations discussed are solely those of the author(s) and are not endorsed by BMJ. BMJ disclaims all liability and responsibility arising from any reliance placed on the content. Where the content includes any translated material, BMJ does not warrant the accuracy and reliability of the translations (including but not limited to local regulations, clinical guidelines, terminology, drug names and drug dosages), and is not responsible for any error and/or omissions arising from translation and adaptation or otherwise.

**Open access** This is an open access article distributed in accordance with the Creative Commons Attribution Non Commercial (CC BY-NC 4.0) license, which permits others to distribute, remix, adapt, build upon this work non-commercially, and license their derivative works on different terms, provided the original work is properly cited, appropriate credit is given, any changes made indicated, and the use is non-commercial. See: <http://creativecommons.org/licenses/by-nc/4.0/>.

## ORCID iDs

Anke Kornuijt <http://orcid.org/0000-0003-3957-4979>

Lieke de Vries <http://orcid.org/0000-0002-5158-9009>

## REFERENCES

- 1 Bullock GS, Garrigues GE, Ledbetter L, *et al*. A systematic review of proposed rehabilitation guidelines following anatomic and reverse shoulder arthroplasty. *J Orthop Sports Phys Ther* 2019;49:337–46.
- 2 Kirsch JM, Namdari S. Rehabilitation after anatomic and reverse total shoulder arthroplasty: A critical analysis review. *JBJS Rev* 2020;8:e0129.
- 3 Friedman RJ, Flurin P-H, Wright TW, *et al*. Comparison of reverse total shoulder arthroplasty outcomes with and without subscapularis repair. *J Shoulder Elbow Surg* 2017;26:662–8.
- 4 Vourazeris JD, Wright TW, Struk AM, *et al*. Primary reverse total shoulder arthroplasty outcomes in patients with subscapularis repair versus tenotomy. *J Shoulder Elbow Surg* 2017;26:450–7.
- 5 de Boer FA, van Kampen PM, Huijsmans PE. The influence of subscapularis tendon reattachment on range of motion in reversed shoulder arthroplasty: a clinical study. *Musculoskelet Surg* 2016;100:121–6.
- 6 Lee J, Consigliere P, Fawzy E, *et al*. Accelerated rehabilitation following reverse total shoulder arthroplasty. *Journal of Shoulder and Elbow Surgery* 2021;30:e545–57.
- 7 Hagen MS, Allahabadi S, Zhang AL, *et al*. A randomized single-blinded trial of early rehabilitation versus immobilization after reverse total shoulder arthroplasty. *J Shoulder Elbow Surg* 2020;29:442–50.
- 8 Edwards PK, Ebert JR, Joss B, *et al*. A randomised trial comparing two rehabilitation approaches following reverse total shoulder arthroplasty. *Shoulder & Elbow* 2021;13:557–72.
- 9 van Essen T, Kornuijt A, de Vries LMA, *et al*. Fast track rehabilitation after reversed total shoulder arthroplasty: a protocol for an international multicentre prospective cohort study. *BMJ Open* 2020;10:e034934.
- 10 Vandenbroucke JP, von Elm E, Altman DG, *et al*. Strengthening the reporting of observational studies in epidemiology (STROBE): explanation and elaboration. *PLoS Med* 2007;4:e297.
- 11 Boileau P, Watkinson DJ, Hatzidakis AM, *et al*. Grammont reverse prosthesis: design, rationale, and biomechanics. *J Shoulder Elbow Surg* 2005;14(1 Suppl S):147S–161S.
- 12 Walker D, Matsuki K, Struk AM, *et al*. Scapulohumeral rhythm in shoulders with reverse shoulder arthroplasty. *Journal of Shoulder and Elbow Surgery* 2015;24:1129–34.
- 13 Levy O, Mullett H, Roberts S, *et al*. The role of anterior deltoid reeducation in patients with massive irreparable degenerative rotator cuff tears. *Journal of Shoulder and Elbow Surgery* 2008;17:863–70.
- 14 Wolff AL, Rosenzweig L. Anatomical and biomechanical framework for shoulder arthroplasty rehabilitation. *J Hand Ther* 2017;30:167–74.
- 15 Kennedy JS, Reinke EK, Friedman LGM, *et al*. Protocol for a multicenter, randomised controlled trial of surgeon-directed home therapy vs. outpatient rehabilitation by physical therapists for reverse total shoulder arthroplasty: the SHORT trial. *Arch Physiother* 2021;11:28.
- 16 Dawson J, Fitzpatrick R, Carr A. Questionnaire on the perceptions of patients about shoulder surgery. *J Bone Joint Surg Br* 1996;78:593–600.
- 17 Berendes T, Pilot P, Willems J, *et al*. Validation of the dutch version of the oxford shoulder score. *J Shoulder Elbow Surg* 2010;19:829–36.
- 18 Rabin R, de Charro F. EQ-5D: a measure of health status from the euroqol group. *Ann Med* 2001;33:337–43.
- 19 Hawker GA, Mian S, Kendzerska T, *et al*. Measures of adult pain: visual analog scale for pain (VAS pain). *Arthritis Care Res (Hoboken)* 2011;63:S240–52.
- 20 Constant CR, Murley AH. A clinical method of functional assessment of the shoulder. *Clin Orthop Relat Res* 1987;214:160–4.
- 21 Barco R, Savvidou OD, Sperling JW, *et al*. Complications in reverse shoulder arthroplasty. *EFORT Open Reviews* 2016;1:72–80.
- 22 Ghasemi A, Zahediasl S. Normality tests for statistical analysis: a guide for non-statisticians. *Int J Endocrinol Metab* 2012;10:486–9.
- 23 Schober P, Vetter TR. Repeated measures designs and analysis of longitudinal data: if at first you do not succeed-try, try again. *Anesth Analg* 2018;127:569–75.
- 24 Parada SA, Flurin P-H, Wright TW, *et al*. Comparison of complication types and rates associated with anatomic and reverse total shoulder arthroplasty. *Journal of Shoulder and Elbow Surgery* 2021;30:811–8.
- 25 Ascione F, Schiavone Panni A, Braile A, *et al*. Problems, complications, and reinterventions in 4893 onlay humeral lateralized reverse shoulder arthroplasties: a systematic review (part I—complications). *J Orthop Traumatol* 2021;22:27.
- 26 Simovitch R, Flurin P-H, Wright T, *et al*. Quantifying success after total shoulder arthroplasty: the substantial clinical benefit. *J Shoulder Elbow Surg* 2018;27:903–11.
- 27 Nyiring MRK, Olsen BS, Amundsen A, *et al*. Minimal clinically important differences (MCID) for the western ontario osteoarthritis of the shoulder index (WOOS) and the oxford shoulder score (OSS). *Patient Relat Outcome Meas* 2021;12:299–306.
- 28 Gromov K, Jørgensen CC, Petersen PB, *et al*. Complications and readmissions following outpatient total hip and knee arthroplasty: a prospective 2-center study with matched controls. *Acta Orthopaedica* 2019;90:281–5.

## Appendix

## Physical therapy guideline: active rehabilitation after reverse shoulder arthroplasty

Phase	Physical therapy	Aim	Remarks
1 (0 – 1 weeks)	<p>Physical therapy starting day 1 postoperative, guided by pain, focus on:</p> <ul style="list-style-type: none"> <li>- Elbow, wrist and hand function</li> <li>- Scapula setting</li> <li>- Guided active shoulder movement (max. 90° anteflexion): raising arms over each other, swinging, external rotation with stick (in supine position)</li> </ul> <p>Advice: 1) pillow may be used under the upperarm/elbow while sleeping supine; and 2) cold packs may be used (2-3 times a day)</p>	<ol style="list-style-type: none"> <li>1. Decrease swelling and pain</li> <li>2. End of 1<sup>st</sup> week: <ul style="list-style-type: none"> <li>- ≥45° anteflexion</li> <li>- ≥45° abduction</li> </ul> </li> <li>- passive, if possible active</li> </ol>	<p>Day 0-1 shoulder sling</p> <p>Day 2: no sling needed Sling only for short moments to relieve any pain</p> <p>Start outpatient physical therapy directly after hospital discharge</p>
2 (2 – 4 weeks)	<p>Start mobilizing the glenohumeral joint, no range of motion (ROM) restrictions: pain guided anteflexion, abduction and external rotation</p> <p>Exercise therapy focused on improving ROM and muscle activation:</p> <ul style="list-style-type: none"> <li>- Extend exercises from 1<sup>st</sup> week</li> <li>- Isometric exercises of deltoid muscle</li> <li>- (Guided) active exercises of deltoid muscle*</li> </ul>	<ol style="list-style-type: none"> <li>1. Decrease swelling and pain</li> <li>2. ROM recovery and muscle activation</li> <li>3. End of week 4: <ul style="list-style-type: none"> <li>- ≥70° anteflexion</li> <li>- ≥70° abduction</li> </ul> </li> <li>- passive, if possible active</li> </ol>	No sling
3 (4 – 6 weeks)	<p>Glenohumeral joint mobilization</p> <p>Exercise therapy focused on improving ROM and muscle activity:</p> <ul style="list-style-type: none"> <li>- Pulley, bench slides (later on wall slides)**</li> <li>- Strengthen deltoid muscle: start from a lying position, progress to (half) sitting and standing</li> <li>- Strengthen scapula-thoracal muscles to optimize scapula position</li> <li>- If the function of the cuff is still present, add exercises for cuff muscles</li> </ul>	<ol style="list-style-type: none"> <li>1. Obtain function and ROM</li> <li>2. End of week 6: <ul style="list-style-type: none"> <li>- ≥90° anteflexion</li> <li>- ≥80° abduction</li> </ul> </li> <li>- passive, if possible active</li> </ol>	Study follow up six weeks postoperative
4 (7 – 12 weeks)	<p>Mobilizing glenohumeral joint, targeting preoperative values or contralateral side</p> <p>Exercise therapy focused on progressing ROM, muscle function, coordination and stability:</p> <ul style="list-style-type: none"> <li>- Strengthen deltoid muscle</li> </ul>	<ol style="list-style-type: none"> <li>1. Recovery to optimal ROM, muscle strength and endurance</li> <li>2. End of week 12: <ul style="list-style-type: none"> <li>- &gt;90° anteflexion</li> <li>- &gt;80° abduction</li> </ul> </li> <li>- passive, if possible active</li> </ol>	<p>Resume mild physical work related activities, if applicable</p> <p>Study follow up three months postoperative</p>



	<ul style="list-style-type: none"> <li>- Strengthen scapula-thoracal muscles</li> <li>- Strengthen all other shoulder muscles</li> <li>- Activities of daily living (ADL) training</li> </ul>	3. Participate in ADL and back to work	<i>Focus on quality of movement</i>
5 (>12 weeks)	Improve ROM and optimize strength, start participating in ADL / work / sports		
<b>Regime:</b>	<ul style="list-style-type: none"> <li>• Sling first day postoperative and if needed during the first week (daytime only)</li> <li>• Allowed to sleep on affected side if tolerated</li> <li>• Driving car and riding bicycle only with sufficient arm muscle control, in consultation with the physical therapist</li> <li>• Lifting close to body</li> </ul>		
* Active exercise of deltoid muscle, gradual progression <sup>6 13</sup>	<p>a) Supine position, bring arm to upright position (assisted by contralateral arm), try to keep this position (figure 3a)</p> <p>b) Keep arm straight and move with comfortable, short arc from upright position (figure 3b)</p> <p>Progression:</p> <ul style="list-style-type: none"> <li>- Amplitude of movement is, pain guided, gradually increased, if shoulder mobility and control increase</li> <li>- Same movement performed with a small weight (0.5 to 1 kg)</li> <li>- Moving the arm against gravity, starting in a semi-sitting position to a sitting position: first within a short amplitude and without any weights</li> </ul>		
** Bench slides progressing to wall slides	<p>a) Bilateral bench slide: patient sitting in front of bench, moving both hands (on a towel/ball) forward and back (anteflexion, figure 3c)</p> <p>Progression:</p> <ul style="list-style-type: none"> <li>- Patient sits alongside bench and performs unilateral bench slide; progressing with trunk forward flexion</li> <li>- Patient performs bench slides using elastic band for resistance</li> <li>- Bench placed in a sloping position, bench slides in a standing position</li> <li>- Wall slides, first by using both arms</li> </ul> <p>b) Wall slides with the operated arm using a towel/ball (figure 3d)</p> <p>Progression:</p> <ul style="list-style-type: none"> <li>- Movement amplitude gradually increasing</li> <li>- Use elastic band for resistance</li> <li>- Lift hand away from wall in elevated position</li> </ul>		
Figure 3a. Arm upright	Figure 3b. Moving straight arm	Figure 3c. Bench slide	Figure 3d. Wall slide
