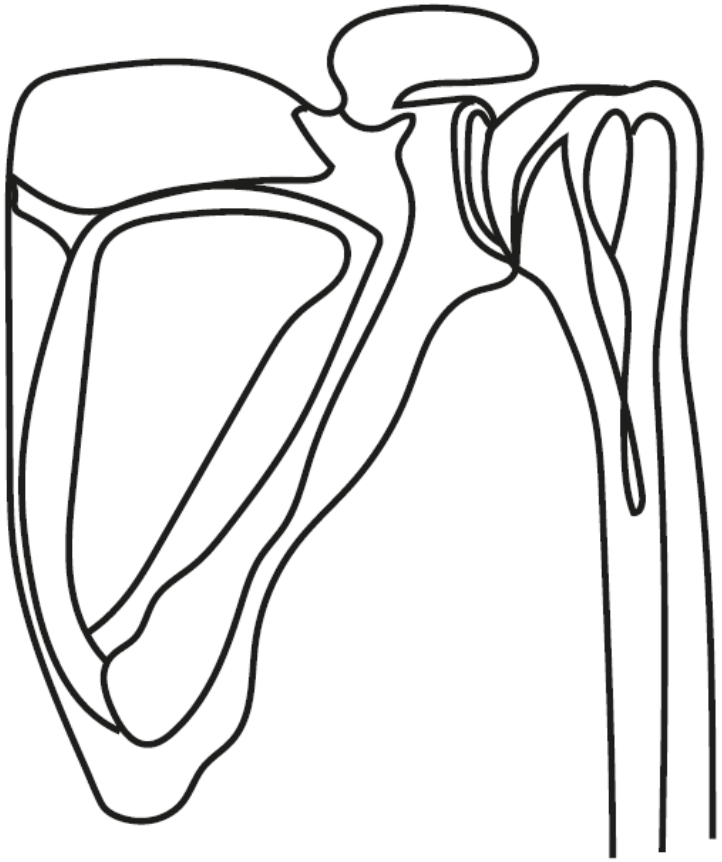

De hyp*mobiele schouder

Valentien Spanhove & Michel Mertens

University of Antwerp
Faculty of Medicine and Health Sciences

PAIN IN MOTION

GHENT UNIVERSITY

Wifi: GTPublic

Inhoud post-conference meeting

Hypomobiele schouder

Hypermobiele schouder

FROZEN SHOULDER	MDI

University of Antwerp | Faculty of Medicine and Health Sciences
GHENT UNIVERSITY
PAIN IN MOTION

Inhoud post-conference meeting

Hypomobiele schouder

Hypermobiele schouder

FROZEN SHOULDER	MDI

University of Antwerp | Faculty of Medicine and Health Sciences
GHENT UNIVERSITY
PAIN IN MOTION

Definitie

Prevalentie-incidentie

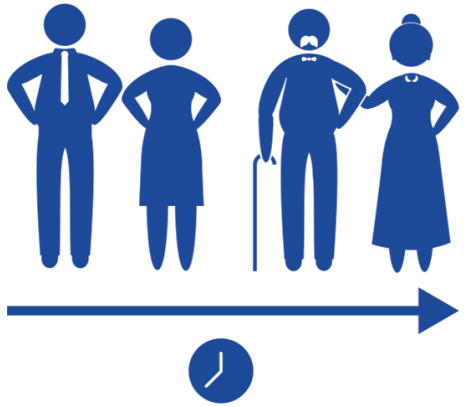

Leeftijd

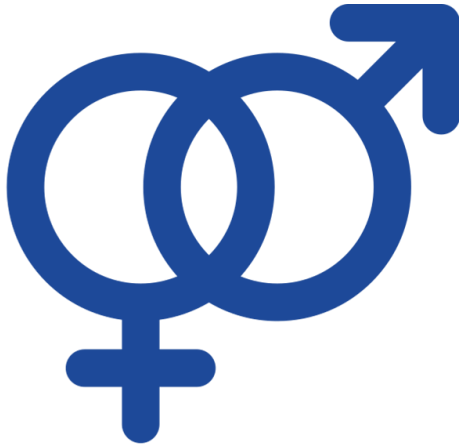

Geslacht

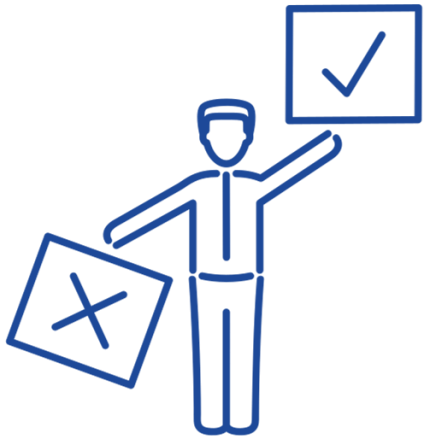

Aangedane zijde

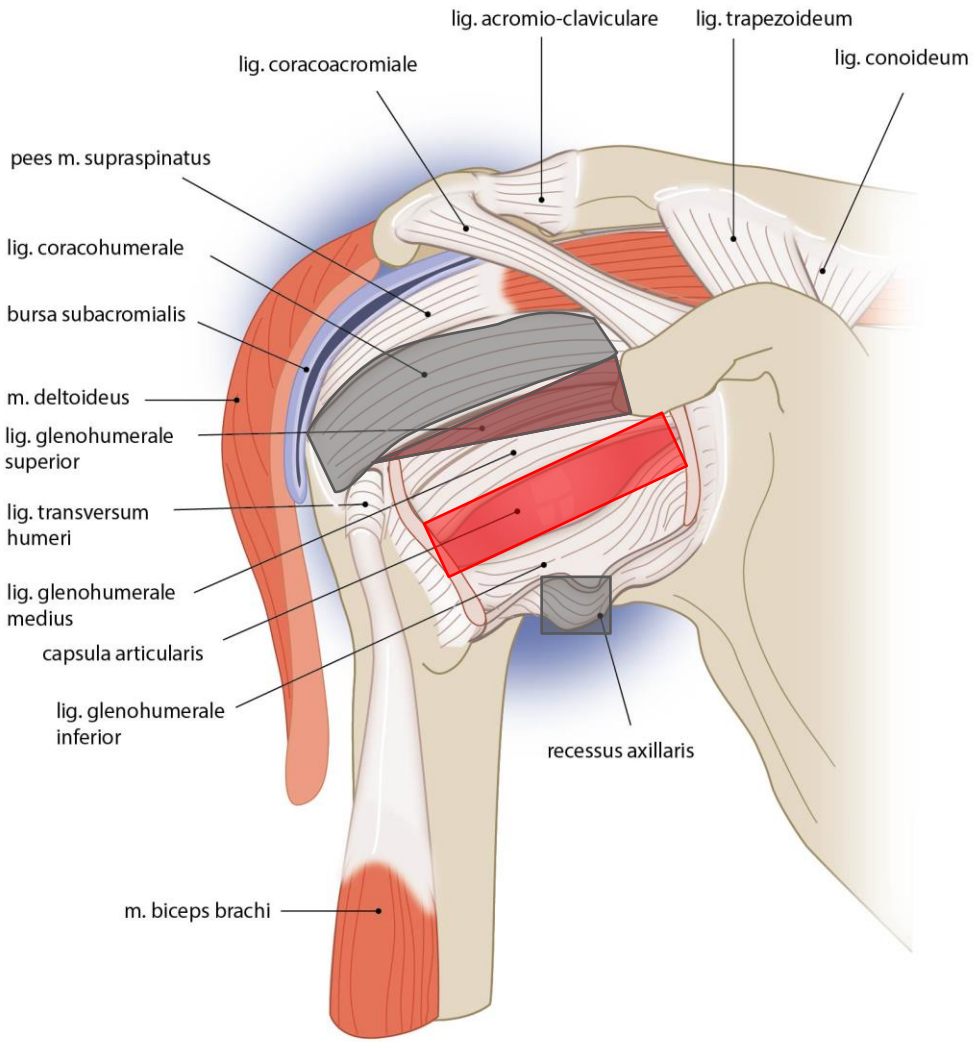

Inflammatie

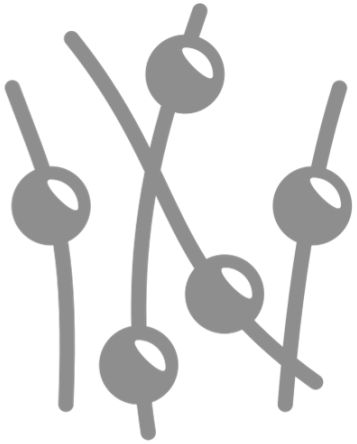

Fibrose

Cho, 2018; Fields, 2019; Do, 2021

University of Antwerp | Faculty of Medicine and Health Sciences
GHENT UNIVERSITY
PAIN IN MOTION

MDI

FROZEN SHOULDER

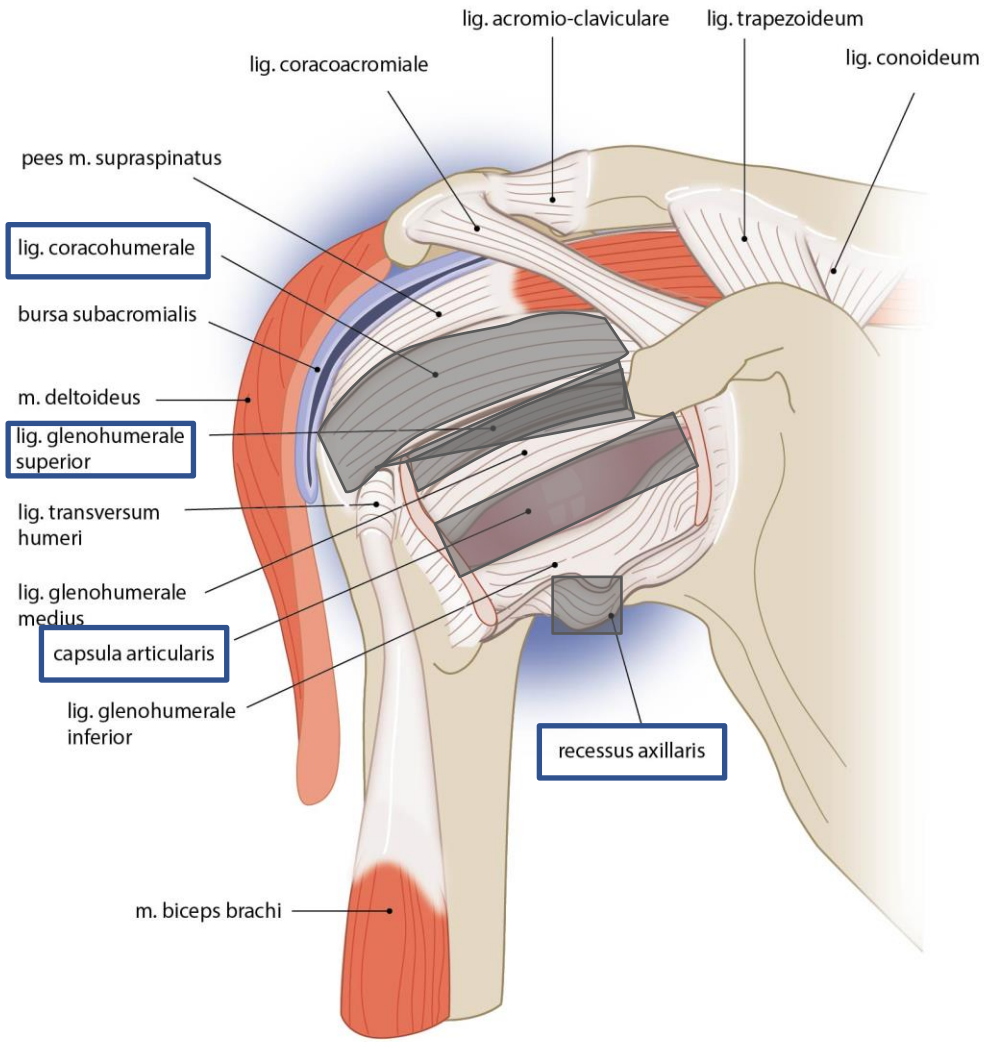

Exorotatie in neutrale positie

Exorotatie in 60° en 90° abductie

Endorotatie

Flexie, abductie of een combinatie

Terry, 1991; Harryman, 1992; Do, 2021

University of Antwerp
Faculty of Medicine and Health Sciences
GHENT UNIVERSITY
PAIN IN MOTION

Diagnose

Klinische criteria

Verwarring

Range of motion

Duur

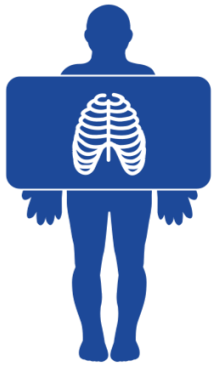

Beeldvorming

Mertens, 2021

University of Antwerp | Faculty of Medicine and Health Sciences
GHENT UNIVERSITY
PAIN IN MOTION

Inhoud post-conference meeting

Hypomobiele schouder

Hypermobiele schouder

FROZEN SHOULDER	MDI

University of Antwerp | Faculty of Medicine and Health Sciences
GHENT UNIVERSITY
PAIN IN MOTION

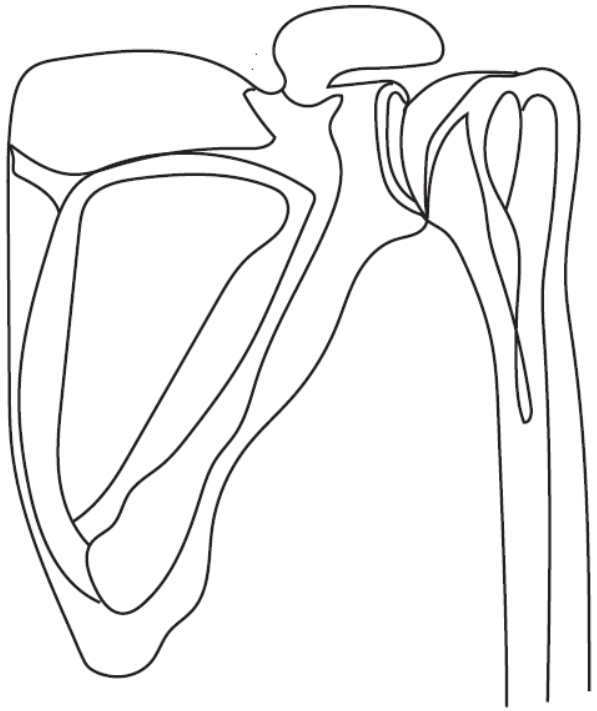

static stabilizers → capsule, ligaments…

and/or

dynamic stabilizers → muscles
scapular position and motion

MDI

FROZEN SHOULDER

University of Antwerp | Faculty of Medicine and Health Sciences
GHENT UNIVERSITY
PAIN IN MOTION

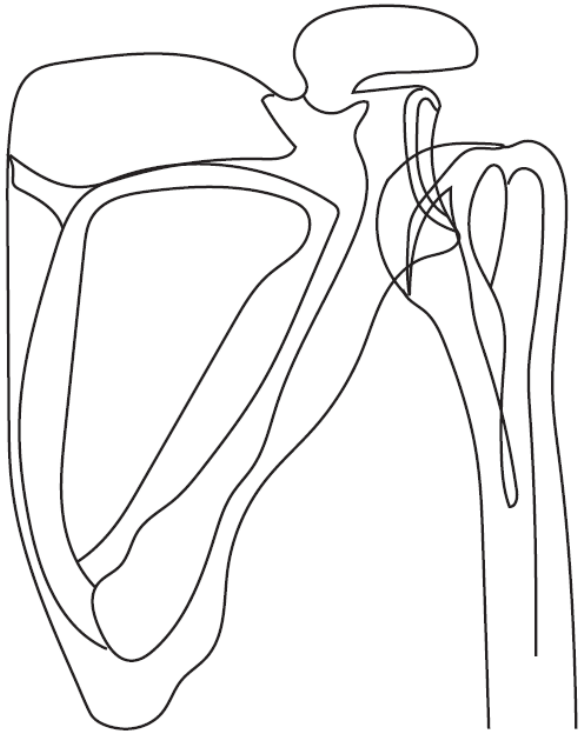

static
stabilizers

and/or

dynamic
stabilizers

capsuloligamentous laxity

altered muscle activation
muscle weakness
altered scapular kinematics

MDI

FROZEN SHOULDER

University of Antwerp
Faculty of Medicine and Health Sciences
GHENT UNIVERSITY
PAIN IN MOTION

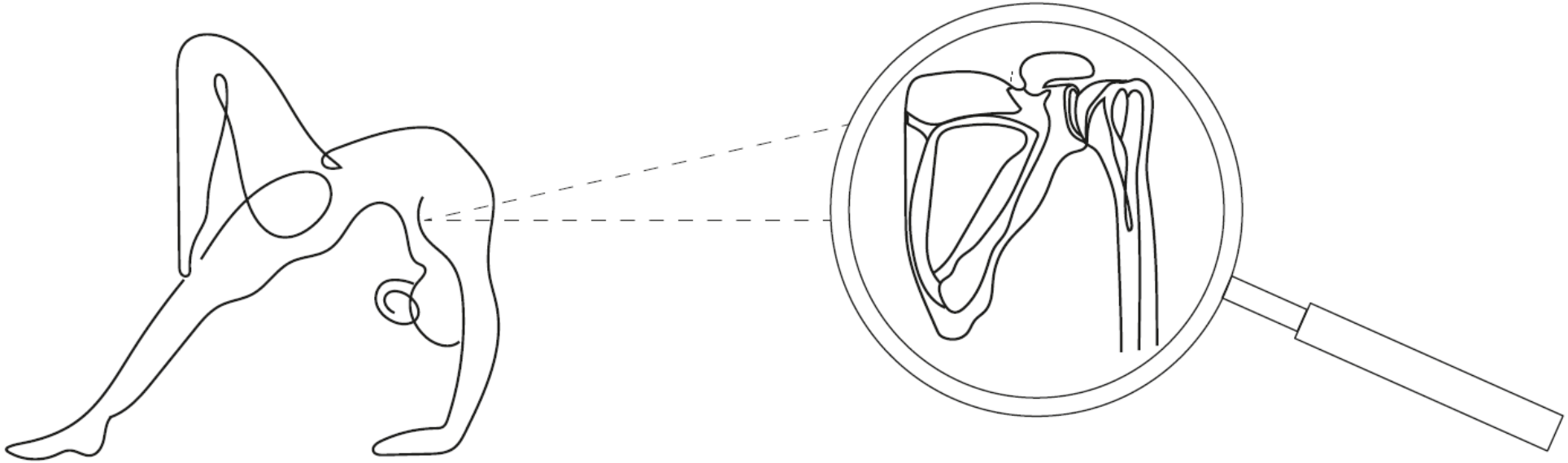

University of Antwerp
Faculty of Medicine and Health Sciences
GHENT UNIVERSITY
PAIN IN MOTION

MDI

FROZEN SHOULDER

JOINT HYPERMOBILITY

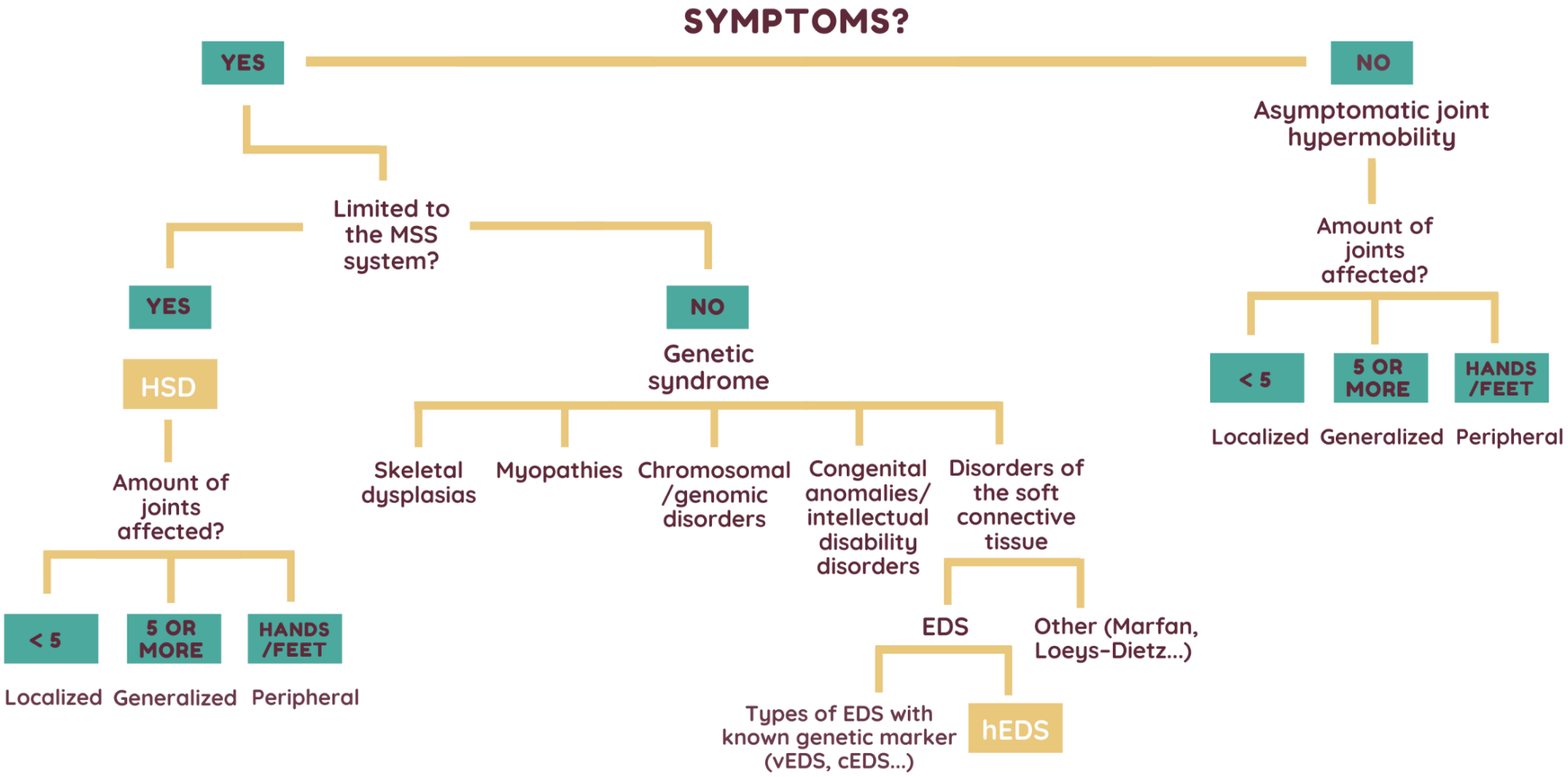

Faculty of Medicine and Health Sciences
GHENT UNIVERSITY
PAIN IN MOTION

MDI

FROZEN SHOULDER

The International Consortium on Ehlers-Danlos Syndromes & Related Disorders
In Association with The Ehlers-Danlos Society

Diagnostic Criteria for Hypermobile Ehlers-Danlos Syndrome (hEDS)

This diagnostic checklist is for doctors across all disciplines to be able to diagnose EDS

Distributed by The Ehlers Danlos Society

Patient name: _____ DOB: _____ DOV: _____ Evaluator: _____

The clinical diagnosis of hypermobile EDS needs the simultaneous presence of all criteria, 1 ***and*** 2 ***and*** 3.

CRITERION 1 – Generalized Joint Hypermobility

One of the following selected:

- ☐ ≥6 pre-pubertal children and adolescents
- ☐ ≥5 pubertal men and woman to age 50
- ☐ ≥4 men and women over the age of 50

Beighton Score: _____/9

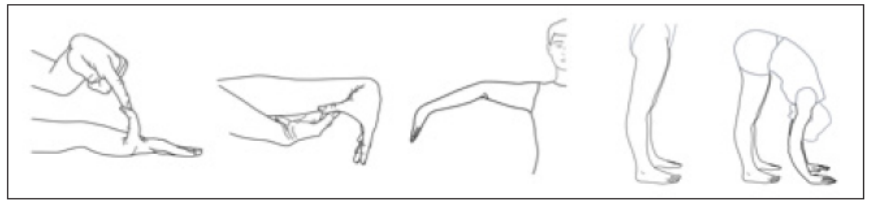

If Beighton Score is one point below age- and sex-specific cut off, two or more of the following must also be selected to meet criterion:

- ☐ Can you now (or could you ever) place your hands flat on the floor without bending your knees?
- ☐ Can you now (or could you ever) bend your thumb to touch your forearm?
- ☐ As a child, did you amuse your friends by contorting your body into strange shapes or could you do the splits?
- ☐ As a child or teenager, did your shoulder or kneecap dislocate on more than one occasion?
- ☐ Do you consider yourself "double jointed"?

University of Antwerp | Faculty of Medicine and Health Sciences
GHENT UNIVERSITY
PAIN IN MOTION

MDI

FROZEN SHOULDER

Start the presentation to see live content. For screen share software, share the entire screen. Get help at **pollev.com/app**

Disclaimer: de voorgestelde stellingen en antwoorden bevatten niet noodzakelijkerwijs de correcte antwoorden. De stellingen zijn bedoeld om discussie op te starten.

Stellingen

1) Onderliggende aandoeningen van MDI
2) Autonome symptomen van de hyp*mobiele schouder
3) Verstoorde scapulaire kinematica
4) Scapulaire kinematica MDI
5) Scapulaire kinematica FS
6) Pathobiomechanica FS
7) Foute geruchten rond de hyp*mobiele schouder
8) Interventies FS
9) Oefentherapie MDI

Stelling 1

Welke onderliggende aandoening uit onderstaande lijst zou in verband kunnen gebracht worden met een hypermobiele schouder?

Start the presentation to see live content. For screen share software, share the entire screen. Get help at **pollev.com/app**

Welke onderliggende aandoening uit onderstaande lijst zou in verband kunnen gebracht worden met een hypermobiele schouder?

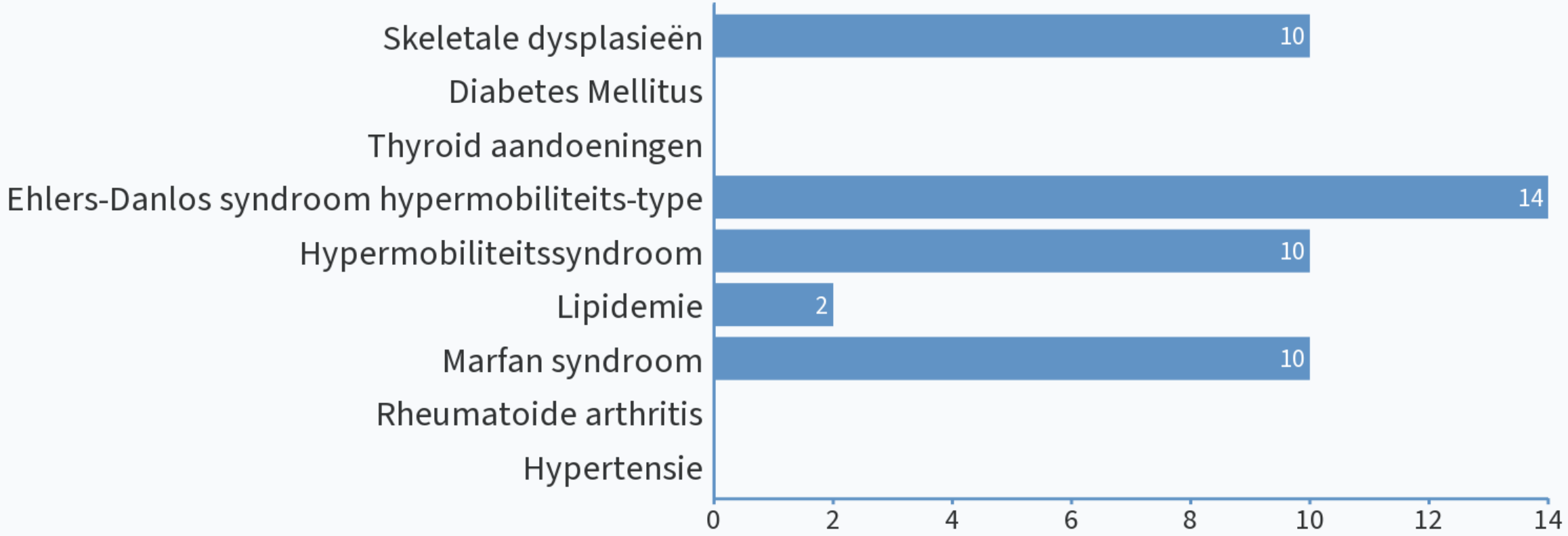

Start the presentation to see live content. For screen share software, share the entire screen. Get help at **pollev.com/app**

Welke onderliggende aandoening uit onderstaande lijst zou in verband kunnen gebracht worden met een hypermobiele schouder?

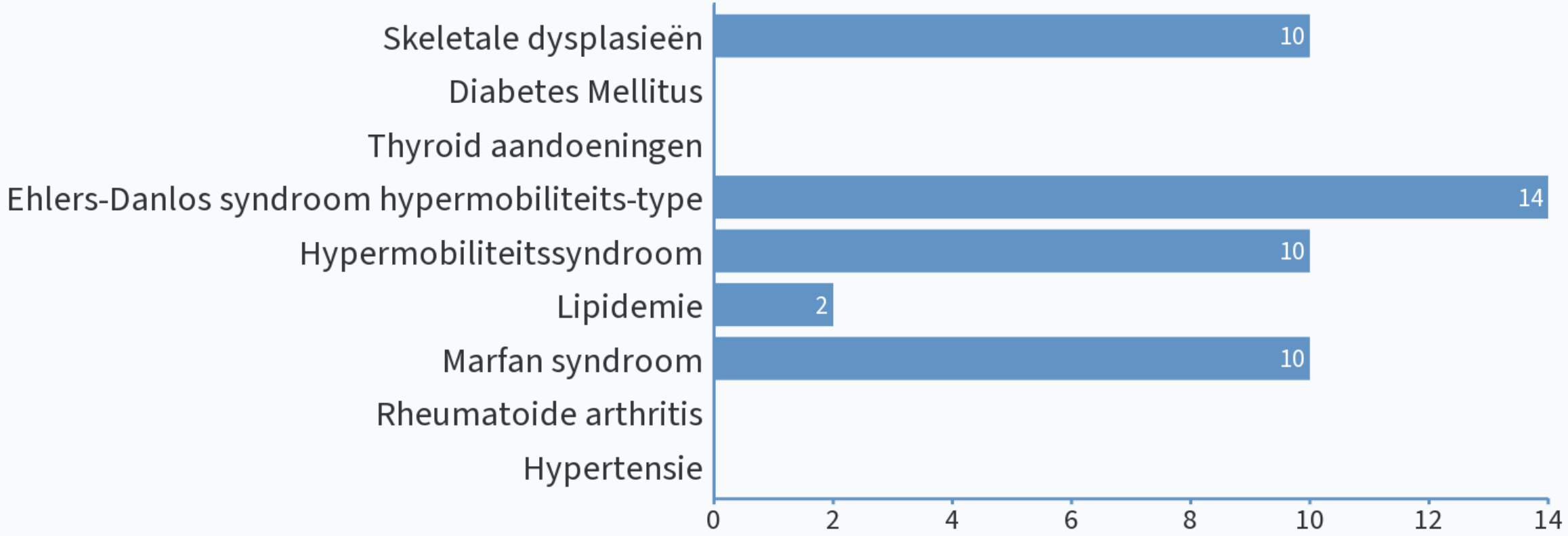

Start the presentation to see live content. For screen share software, share the entire screen. Get help at **pollev.com/app**

Stelling 1

MDI

→ Isolated

→ GJH

University of Antwerp
Faculty of Medicine and Health Sciences
GHENT UNIVERSITY
PAIN IN MOTION

Stelling 1

MDI

→ Isolated

→ **GJH**

University of Antwerp
Faculty of Medicine and Health Sciences
GHENT UNIVERSITY
PAIN IN MOTION

Stelling 1

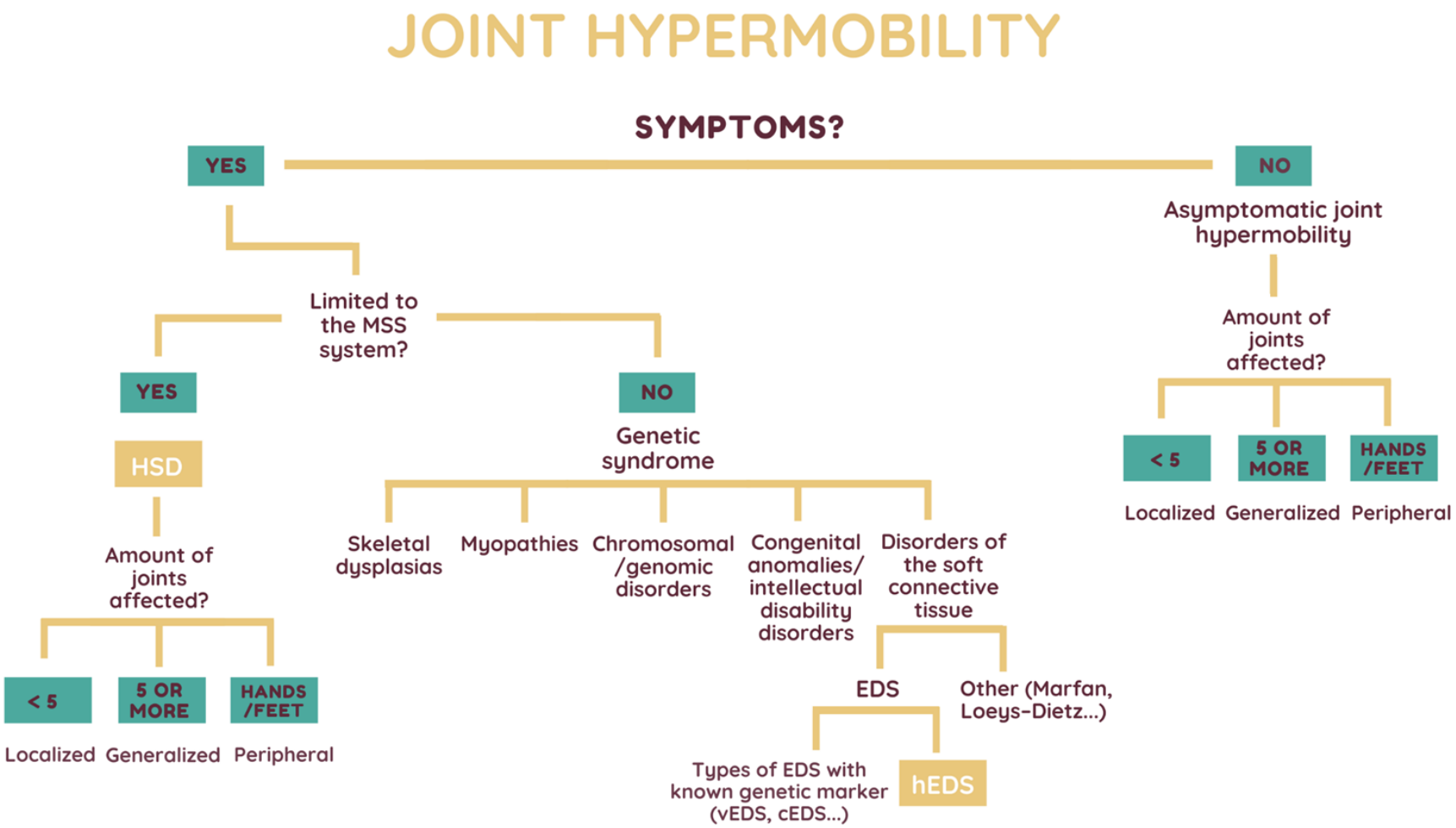

MDI

FROZEN SHOULDER

of Antwerp
Faculty of Medicine and Health Sciences
GHENT UNIVERSITY
PAIN IN MOTION

Stelling 1

Prevalentie van comorbiditeiten, incidentie van frozen shoulder en comorbiditeiten als risicofactor

Comorbiditeit	Prevalentie in frozen shoulder	Incidentie van frozen shoulder	Risico op frozen shoulder
Diabetes mellitus	11%-30%	10.8%-58.8%	1.05-1.72
Thyroid aandoeningen	2%-34%	10.9%	1.22-8.87
Dyslipidemie	26%	-	1.01-1.93
Hypertensie	22%	-	0.27-1.21
Rheumatoide arthritis	-	-	1.54

Cakir, 2003; Schiefer, 2007; Milgrom, 2008; Huang, 2014; Lo, 2014; Zreik, 2016; Inayat, 2017; Juel, 2017; Gumina, 2018; Tzeng, 2019; Cohen, 2020; Park, 2020; Wang, 2021

Stellingen

1) Onderliggende aandoeningen van MDI
2) Autonome symptomen van de hyp*mobiele schouder
3) Verstoorde scapulaire kinematica
4) Scapulaire kinematica MDI
5) Scapulaire kinematica FS
6) Pathobiomechanica FS
7) Foute geruchten rond de hyp*mobiele schouder
8) Interventies FS
9) Oefentherapie MDI

Stelling 2

Welke van onderstaande autonome symptomen komen frequent voor bij zowel frozen shoulder als MDI?

- Vasomotor dysfunctie
- Gastro-intestinale dysfunctie
- Blaas dysfunctie
- Pupillomotor dysfunctie
- Orthostatische intolerantie

Start the presentation to see live content. For screen share software, share the entire screen. Get help at **pollev.com/app**

Welke van onderstaande autonome symptomen komen frequent voor bij zowel frozen shoulder als MDI?

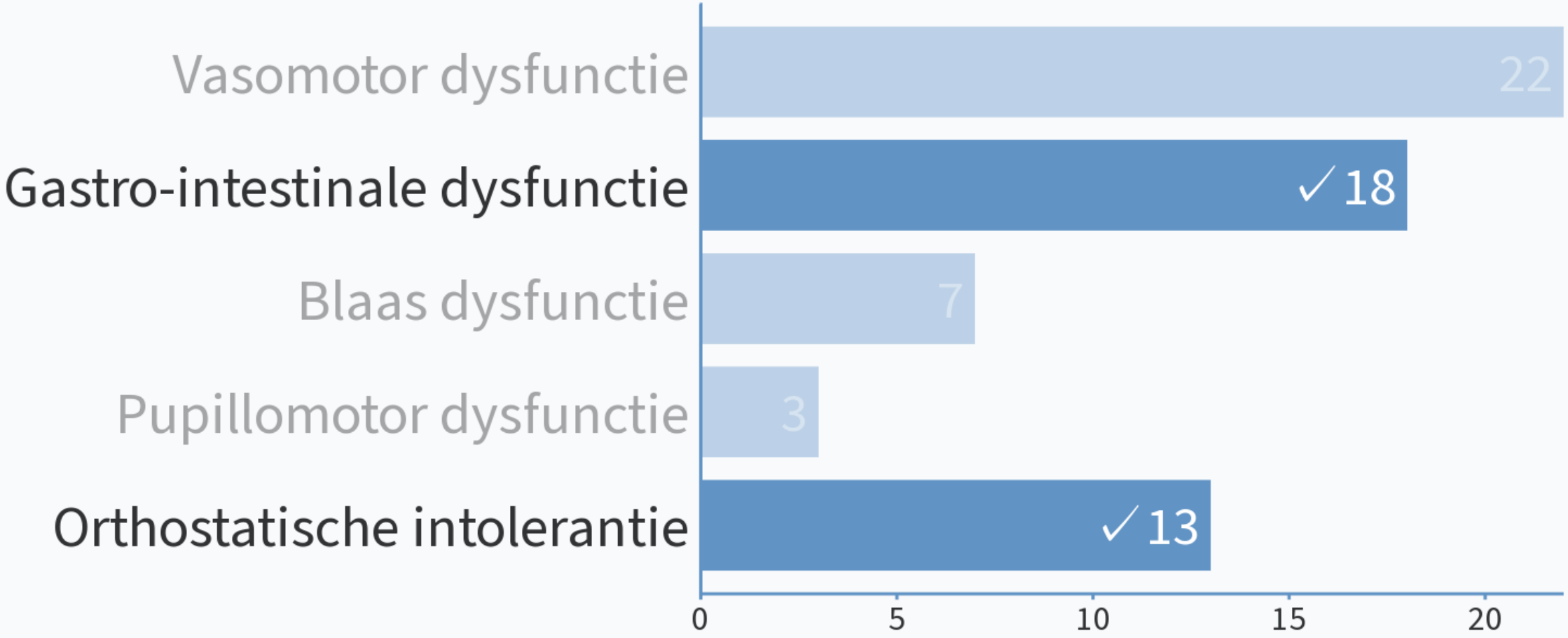

Start the presentation to see live content. For screen share software, share the entire screen. Get help at **pollev.com/app**

Welke van onderstaande autonome symptomen komen frequent voor bij zowel frozen shoulder als MDI?

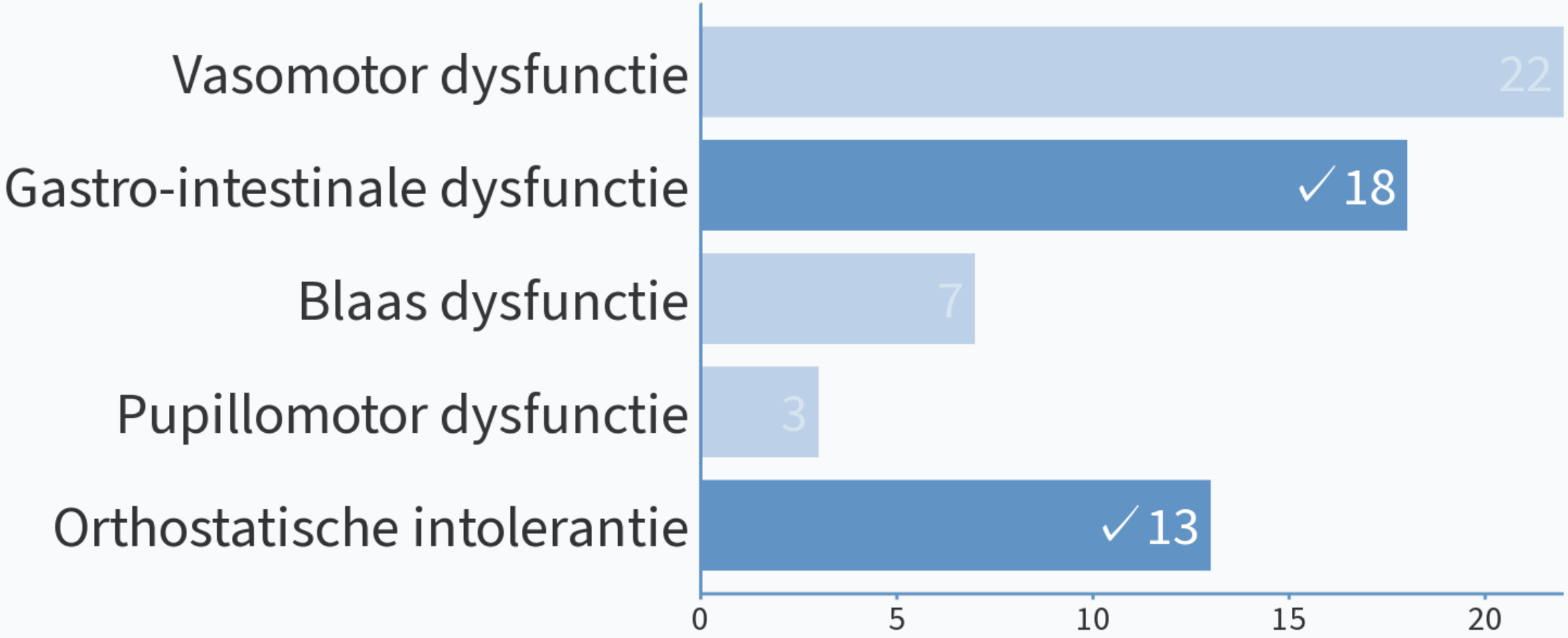

Start the presentation to see live content. For screen share software, share the entire screen. Get help at **pollev.com/app**

Stelling 2

- MDI as part of hEDS/HSD
- Total autonomic symptom burden in EDS-HT > controls, cEDS and vEDS but = FM *(De Wandele et al. 2014)*
- Orthostatic and gastrointestinal complaints *(De Wandele et al. 2014)*

Stelling 2

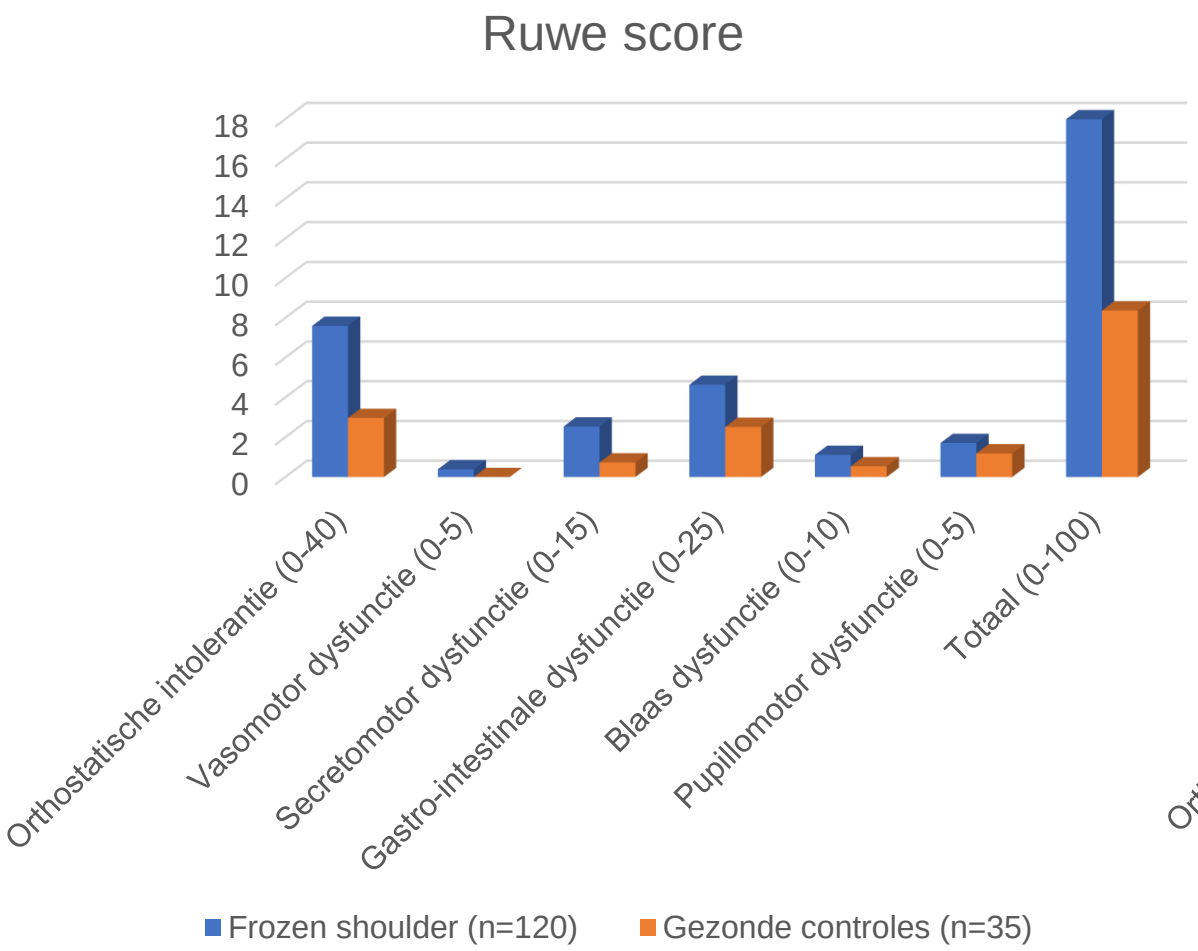

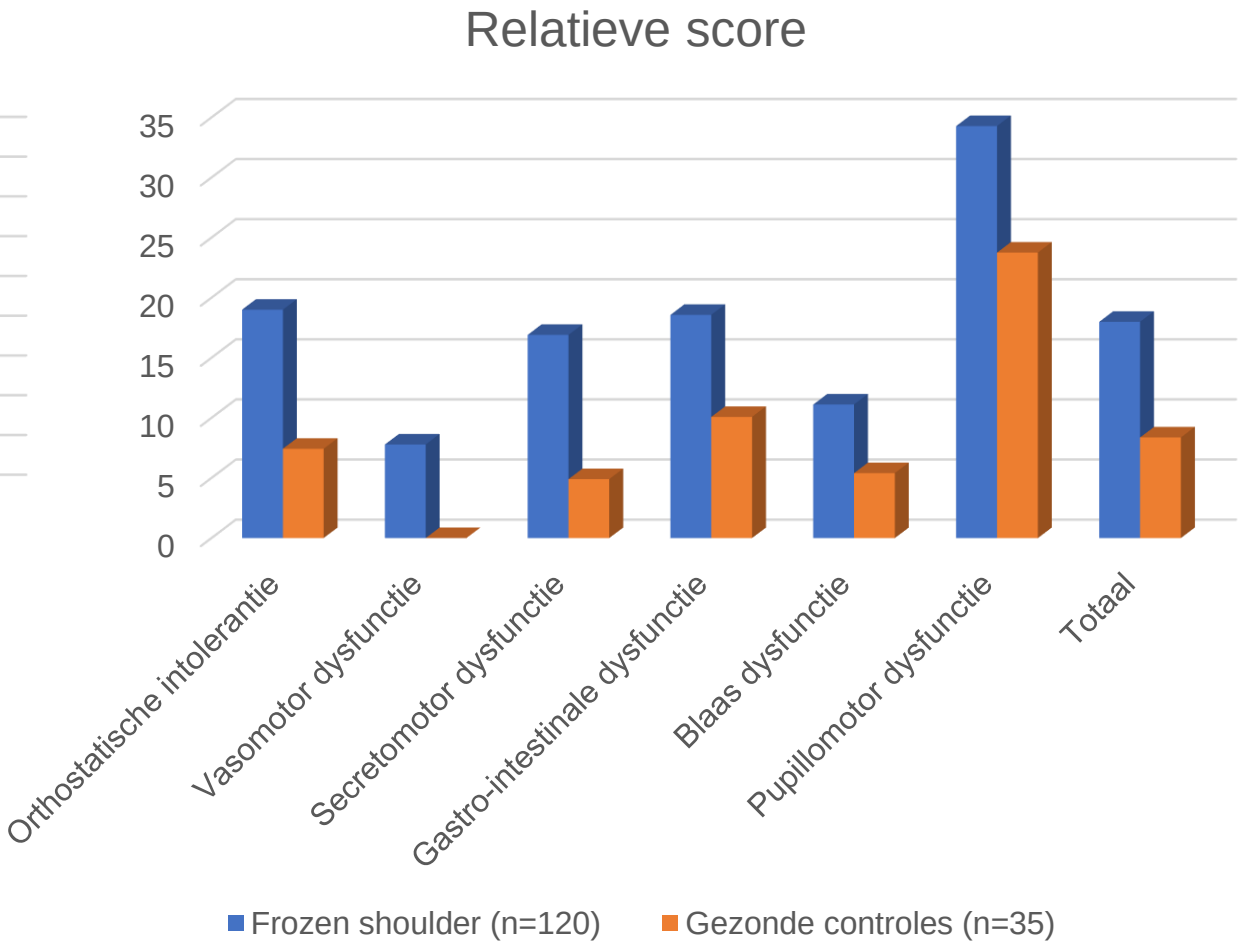

Unpublished data

University of Antwerp | Faculty of Medicine and Health Sciences
GHENT UNIVERSITY
PAIN IN MOTION

MDI

FROZEN SHOULDER

Stellingen

1) Onderliggende aandoeningen van MDI
2) Autonome symptomen van de hyp*mobiele schouder
3) Verstoorde scapulaire kinematica
4) Scapulaire kinematica MDI
5) Scapulaire kinematica FS
6) Pathobiomechanica FS
7) Foute geruchten rond de hyp*mobiele schouder
8) Interventies FS
9) Oefentherapie MDI

Stelling 3

Bij welke aandoening is er reeds evidentie dat de scapulaire kinematica verstoord is?

Frozen shoulder

Multidirectionele instabiliteit

Beiden

Start the presentation to see live content. For screen share software, share the entire screen. Get help at **pollev.com/app**

Bij welke aandoening is er reeds evidentie dat de scapulaire kinematica verstoord is?

Frozen shoulder

Multidirectionele instabiliteit

Beiden

Start the presentation to see live content. For screen share software, share the entire screen. Get help at **pollev.com/app**

Bij welke aandoening is er reeds evidentie dat de scapulaire kinematica verstoord is?

Frozen shoulder

Multidirectionele instabiliteit

Beiden

Start the presentation to see live content. For screen share software, share the entire screen. Get help at **pollev.com/app**

Stellingen

1) Onderliggende aandoeningen van MDI
2) Autonome symptomen van de hyp*mobiele schouder
3) Verstoorde scapulaire kinematica
4) Scapulaire kinematica MDI
5) Scapulaire kinematica FS
6) Pathobiomechanica FS
7) Foute geruchten rond de hyp*mobiele schouder
8) Interventies FS
9) Oefentherapie MDI

Stelling 4

Aan welke scapulaire dysfunctie denkt u bij multidirectionele instabiliteit?

Verminderde anterieure tilt

Verminderde opwaarste rotatie

Verminderde interne rotatie

Start the presentation to see live content. For screen share software, share the entire screen. Get help at **pollev.com/app**

Aan welke scapulaire dysfunctie denkt u bij multidirectionele instabiliteit?

Verminderde anterieure tilt

Verminderde opwaarste rotatie

Verminderde interne rotatie

Start the presentation to see live content. For screen share software, share the entire screen. Get help at **pollev.com/app**

Aan welke scapulaire dysfunctie denkt u bij multidirectionele instabiliteit?

Verminderde anterieure tilt

Verminderde opwaarste rotatie

Verminderde interne rotatie

Start the presentation to see live content. For screen share software, share the entire screen. Get help at **pollev.com/app**

Stelling 3-4

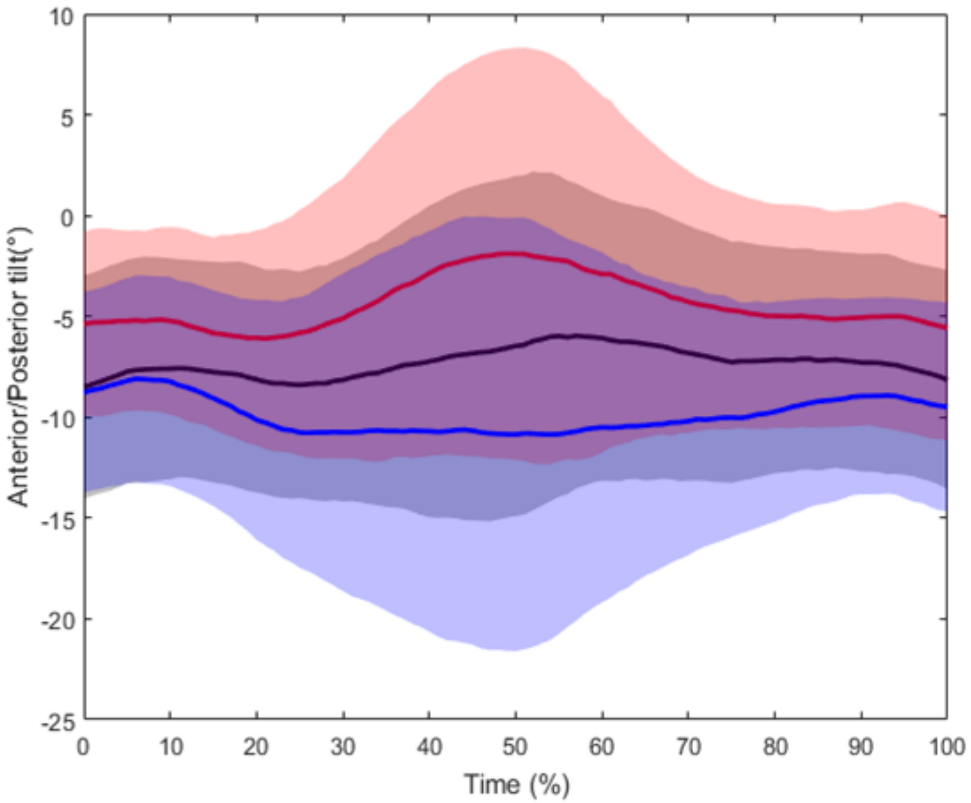

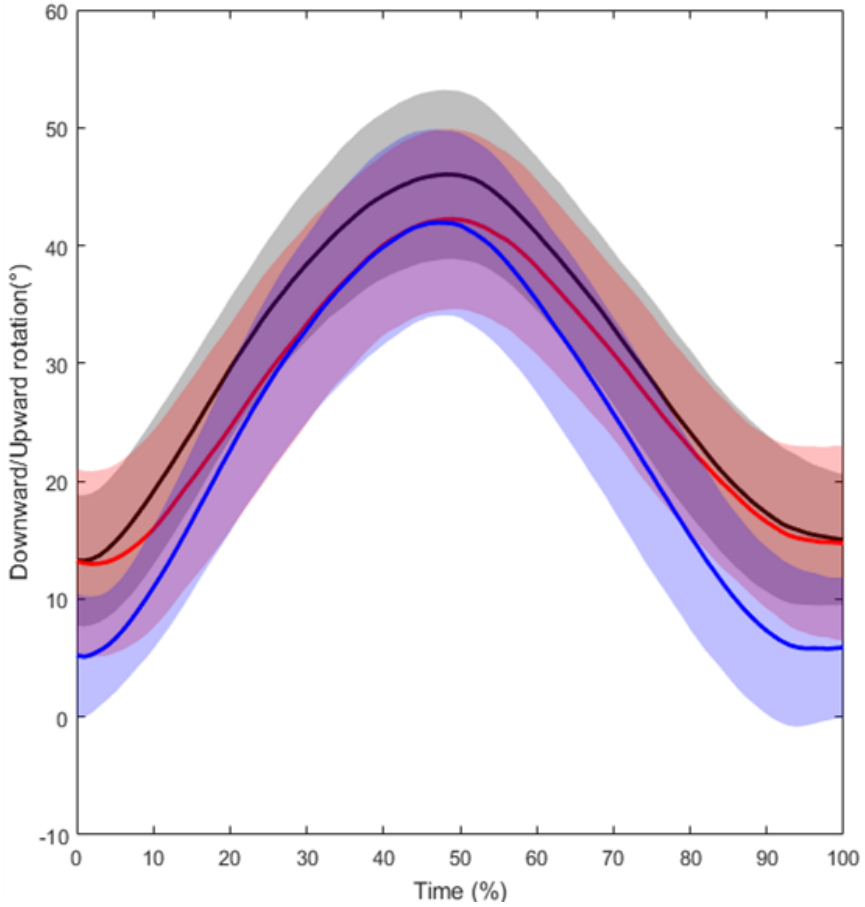

University of Antwerp
Faculty of Medicine and Health Sciences
GHENT UNIVERSITY
PAIN IN MOTION

MDI

FROZEN SHOULDER

Stellingen

1) Onderliggende aandoeningen van MDI
2) Autonome symptomen van de hyp*mobiele schouder
3) Verstoorde scapulaire kinematica
4) Scapulaire kinematica MDI
5) Scapulaire kinematica FS
6) Pathobiomechanica FS
7) Foute geruchten rond de hyp*mobiele schouder
8) Interventies FS
9) Oefentherapie MDI

Stelling 5

En aan welke scapulaire dysfunctie denkt u bij een frozen shoulder?

- Verminderde anterieure tilt
- Vergrote opwaartse rotatie
- Verminderde interne rotatie
- Verminderde protractie

Start the presentation to see live content. For screen share software, share the entire screen. Get help at **pollev.com/app**

En aan welke scapulaire dysfunctie denkt u bij een frozen shoulder?

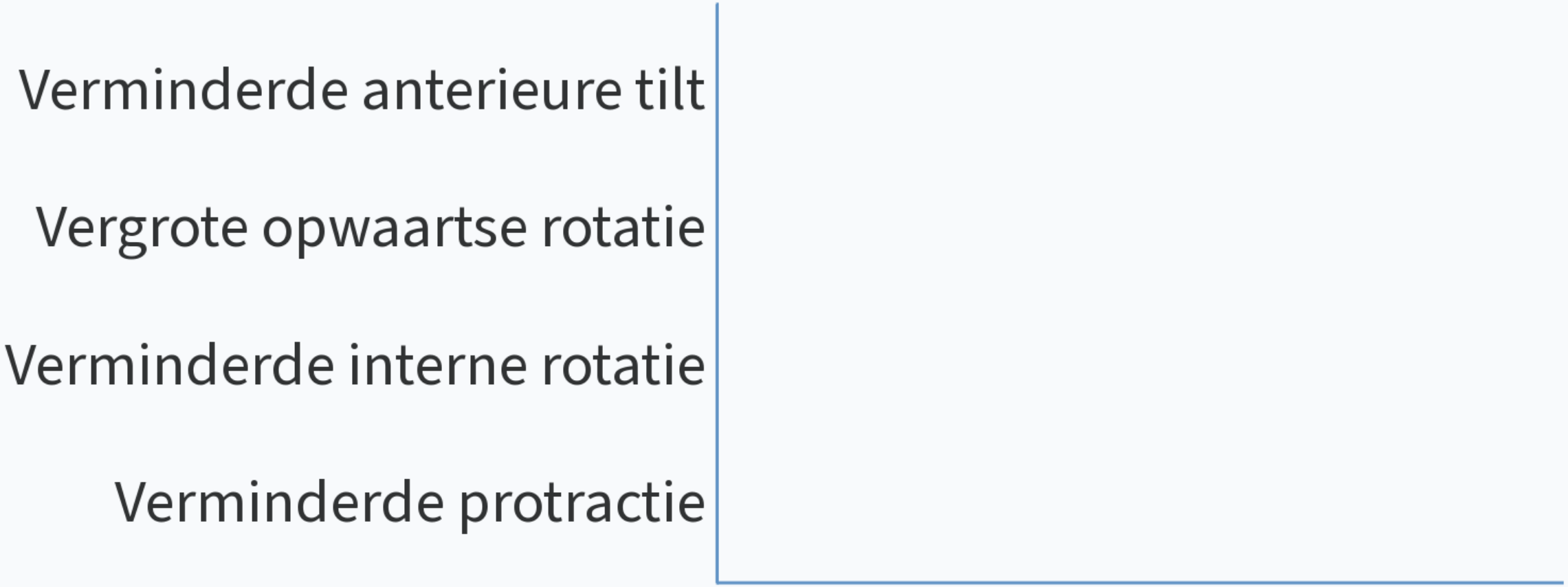

Start the presentation to see live content. For screen share software, share the entire screen. Get help at **pollev.com/app**

En aan welke scapulaire dysfunctie denkt u bij een frozen shoulder?

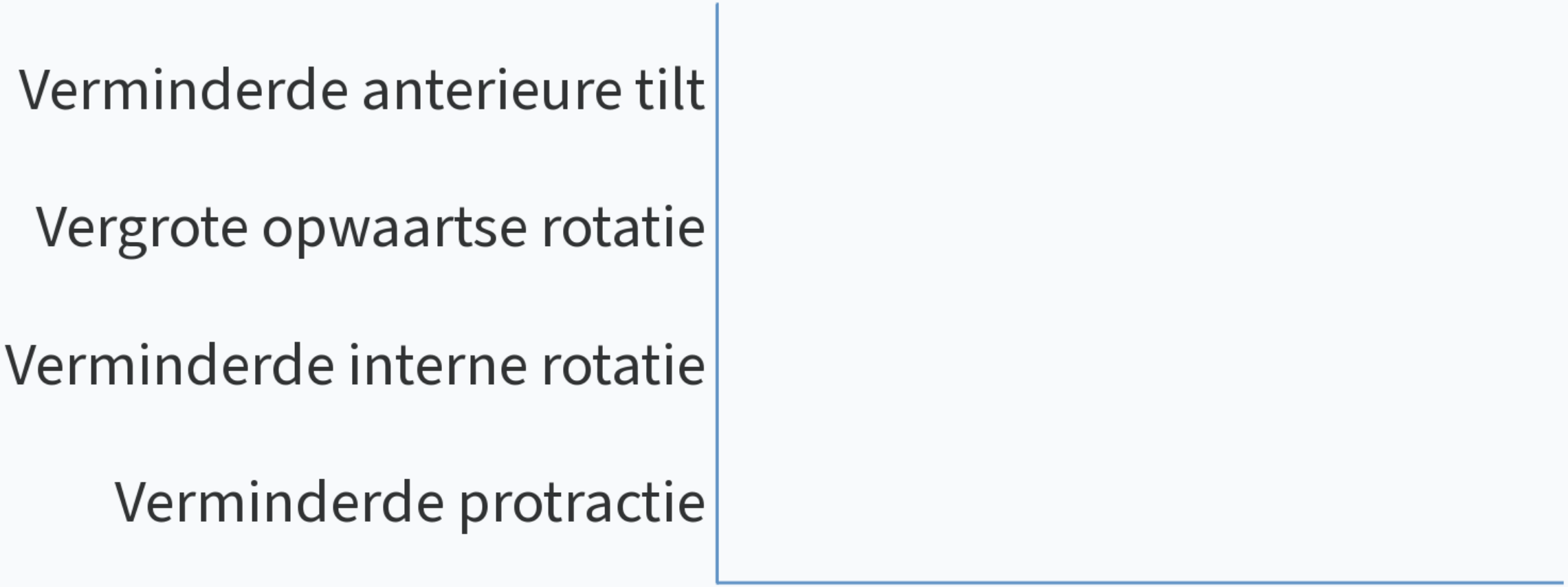

Start the presentation to see live content. For screen share software, share the entire screen. Get help at **pollev.com/app**

Stelling 5

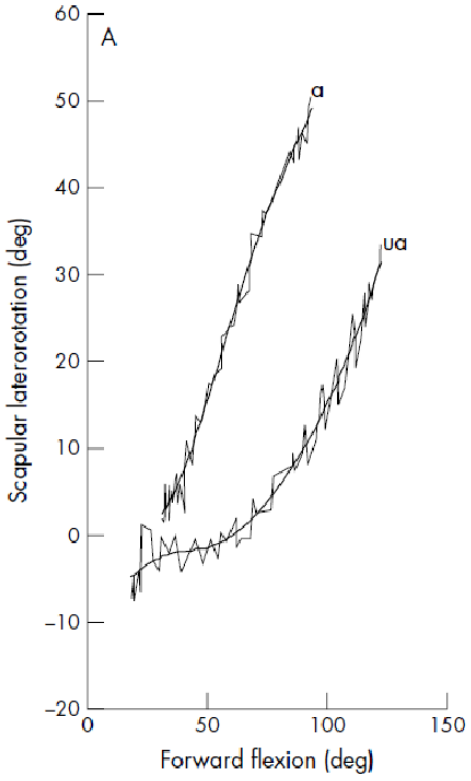

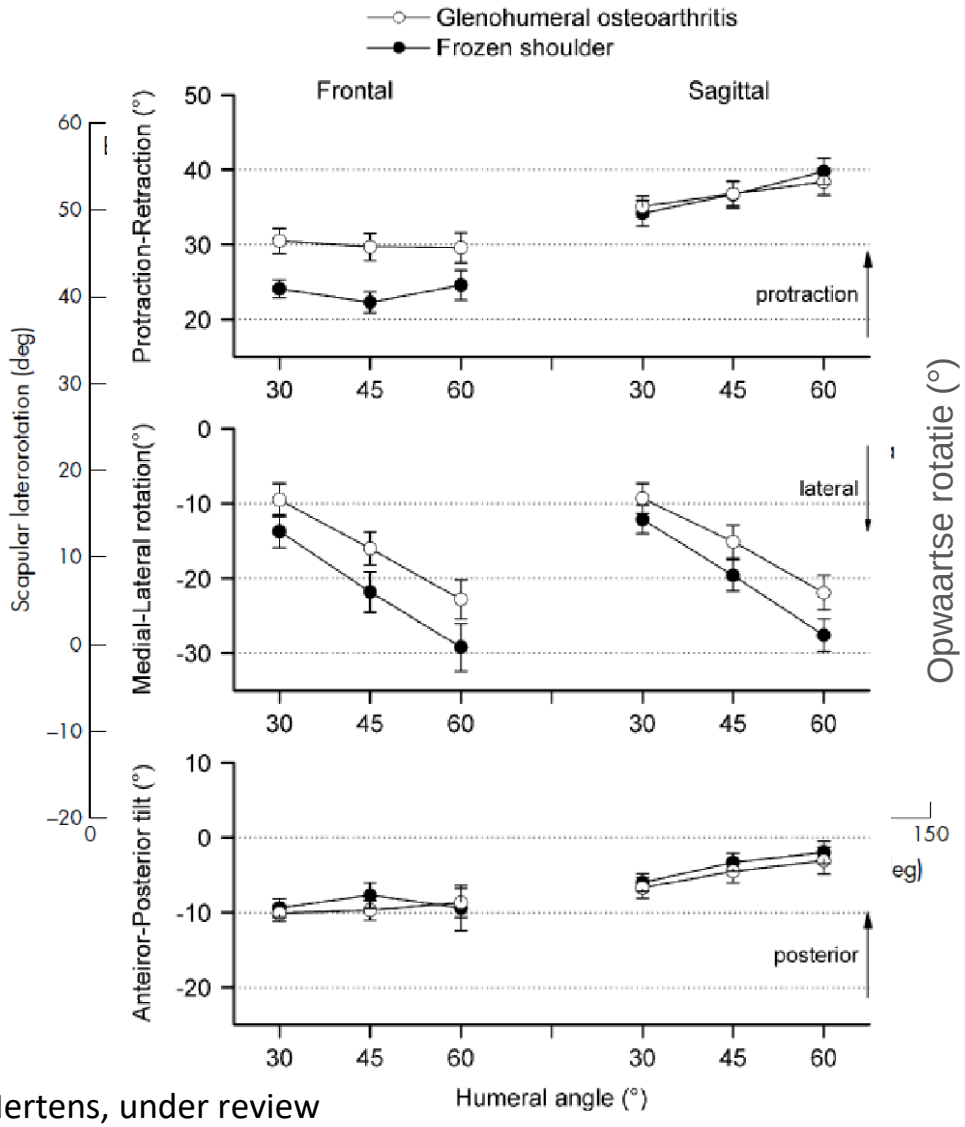

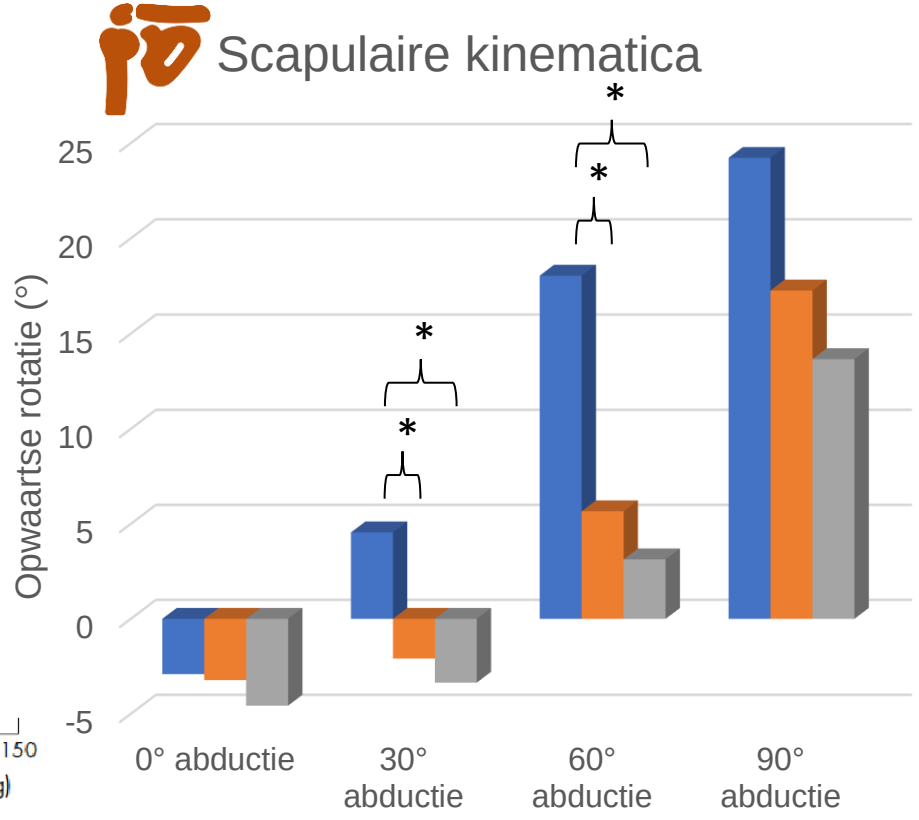

Vermeulen, 2002; Fayad, 2008; Mertens, under review

University of Antwerp
Faculty of Medicine and Health Sciences
GHENT UNIVERSITY
PAIN IN MOTION

MDI

FROZEN SHOULDER

Stellingen

1) Onderliggende aandoeningen van MDI
2) Autonome symptomen van de hyp*mobiele schouder
3) Verstoorde scapulaire kinematica
4) Scapulaire kinematica MDI
5) Scapulaire kinematica FS
6) Pathobiomechanica FS
7) Foute geruchten rond de hyp*mobiele schouder
8) Interventies FS
9) Oefentherapie MDI

Stelling 6

Bij patiënten met een frozen shoulder wordt een vergrote opwaartse rotatie gevonden. Voor welke van onderstaande verklaringen is er ook wetenschappelijk bewijs?

- Verminderde glenohumerale ROM
- Veranderde spieractiviteit rondom de schouder
- Beiden

Start the presentation to see live content. For screen share software, share the entire screen. Get help at **pollev.com/app**

Bij patiënten met een frozen shoulder wordt een vergrote opwaartse rotatie gevonden. Voor welke van onderstaande verklaringen is er ook wetenschappelijk bewijs?

Verminderde glenohumerale ROM

Veranderde spieractiviteit rondom de schouder

Beiden

Start the presentation to see live content. For screen share software, share the entire screen. Get help at **pollev.com/app**

Bij patiënten met een frozen shoulder wordt een vergrote opwaartse rotatie gevonden. Voor welke van onderstaande verklaringen is er ook wetenschappelijk bewijs?

Verminderde glenohumerale ROM

Veranderde spieractiviteit rondom de schouder

Beiden

Start the presentation to see live content. For screen share software, share the entire screen. Get help at **pollev.com/app**

Stelling 6

Beperkte ROM

Intensieve passieve eindstandige mobilisatietechnieken

↑ ROM flexie, abductie, exorotatie van 15-52°

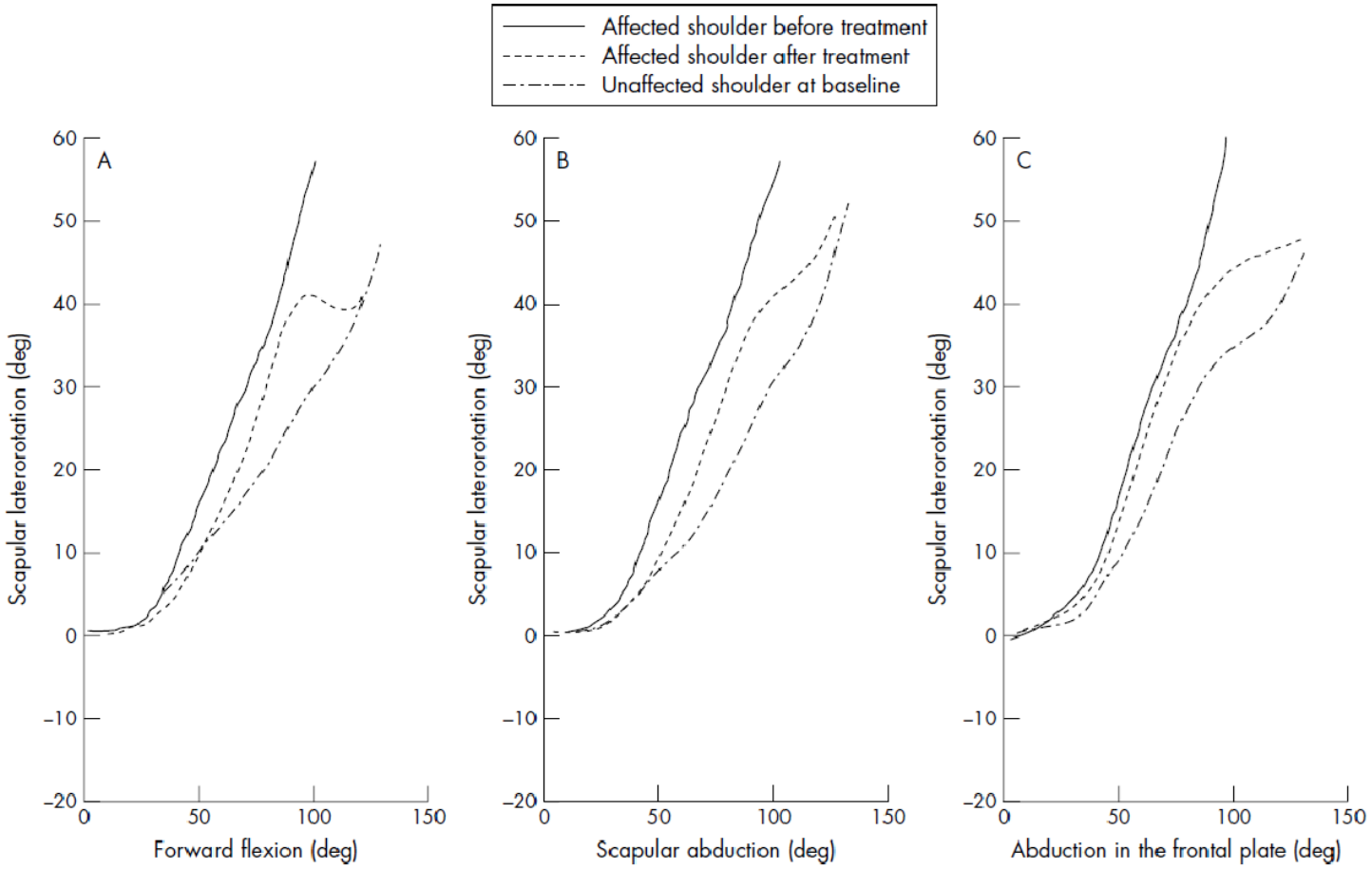

Vermeulen, 2002

University of Antwerp
Faculty of Medicine and Health Sciences
GHENT UNIVERSITY
PAIN IN MOTION

MDI

FROZEN SHOULDER

Stelling 6

Spieractiviteit

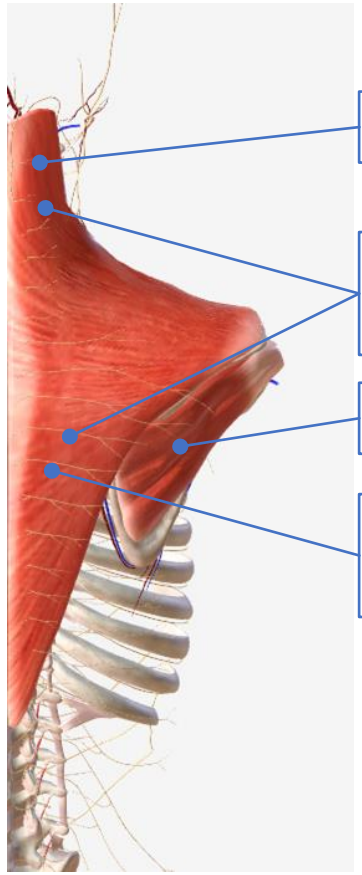

UT: ↑ Tijdens elevatie in 3 richtingen op 60° en 120°

↑ ratio UT/LT op 120° tov 60° bij FS en gezond
Ratio UT/LT FS>gezond op 60° en 120°

IS: ↓ tijdens dynamische scaptie

LT: ↑ Tijdens elevatie in 3 richtingen op 120°
↓ tijdens dynamische scaptie

PM: ↑ Tijdens hand op de rug

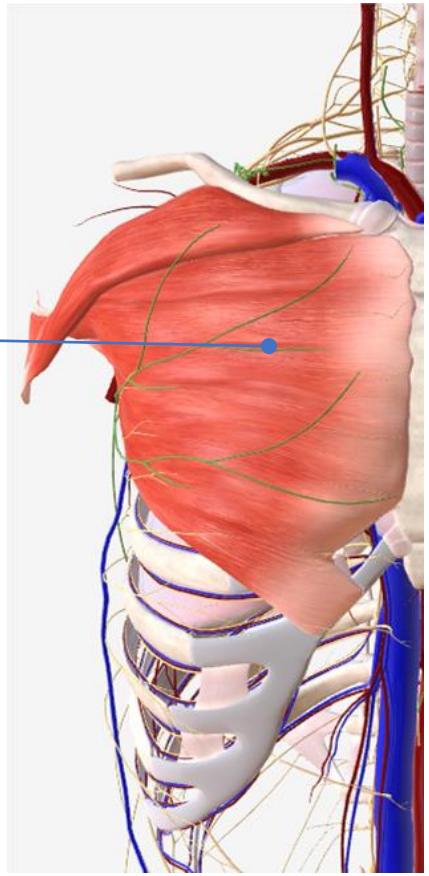

Lin, 2005; Shih, 2017; images from BioDigital

Stellingen

1) Onderliggende aandoeningen van MDI
2) Autonome symptomen van de hyp*mobiele schouder
3) Verstoorde scapulaire kinematica
4) Scapulaire kinematica MDI
5) Scapulaire kinematica FS
6) Pathobiomechanica FS
7) Foute geruchten rond de hyp*mobiele schouder
8) Interventies FS
9) Oefentherapie MDI

Stelling 7

Over zowel de hypo-als hypermobiele schouder gaan wat 'foute' geruchten de ronde.

Welke van onderstaande stellingen is het MINST correct?

- Het kan zinvol zijn om te oefenen met gewichtjes in de behandeling van een schouder met MDI
- Tijdens het klinisch onderzoek van een MDI schouder zal er niet altijd een vergrote range of motion zijn
- Frozen shoulder volgt karakteristiek 3 fases en is een zelf-limiterende aandoening
- Tijdens de behandeling van een frozen shoulder is het toepassen van een corticosteroïde injectie vooral zinvol voor het intreden van de bewegingsbeperking

Start the presentation to see live content. For screen share software, share the entire screen. Get help at **pollev.com/app**

Over zowel de hypo-als hypermobiele schouder gaan wat 'foute' geruchten de ronde.

Welke van onderstaande stellingen is het MINST correct?

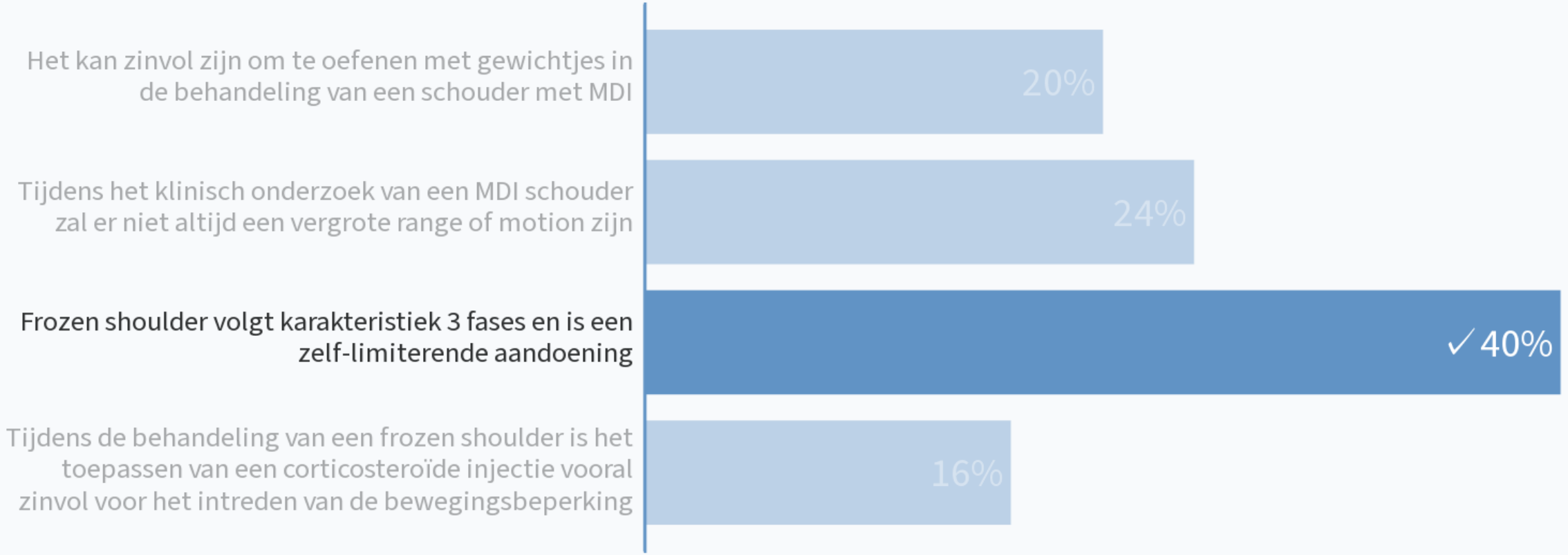

Start the presentation to see live content. For screen share software, share the entire screen. Get help at **pollev.com/app**

Over zowel de hypo-als hypermobiele schouder gaan wat 'foute' geruchten de ronde.

Welke van onderstaande stellingen is het MINST correct?

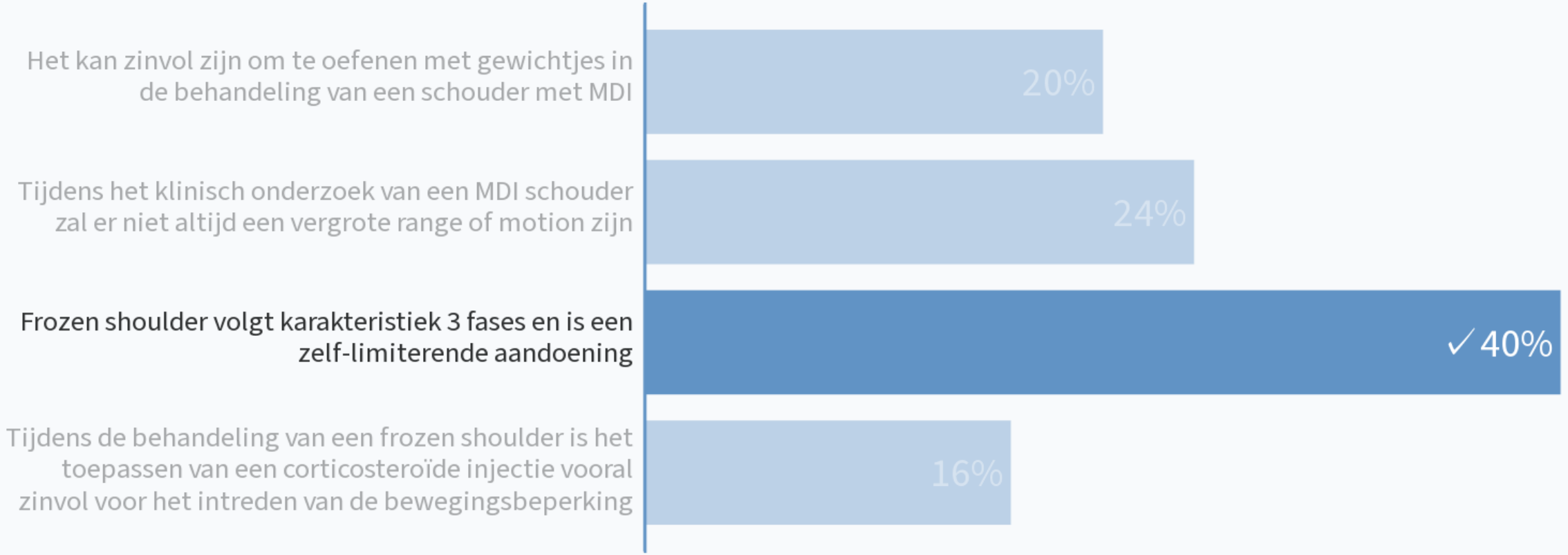

Start the presentation to see live content. For screen share software, share the entire screen. Get help at **pollev.com/app**

Stelling 7

Regarding weights…

University of Antwerp | Faculty of Medicine and Health Sciences
GHENT UNIVERSITY
PAIN IN MOTION

Stelling 7

Can certainly be of use

- monitor the patient's symptoms
- muscle strengthening
- scapular external rotation

University of Antwerp | Faculty of Medicine and Health Sciences
GHENT UNIVERSITY
PAIN IN MOTION

Stelling 7



inferior (sub)luxation
shoulder pain

- sulcus sign?
- ≥2 kg has to be avoided (in the beginning)
- isometric shoulder/elbow extension

University of Antwerp | Faculty of Medicine and Health Sciences
GHENT UNIVERSITY
PAIN IN MOTION

Stelling 7

Regarding clinical exam…

University of Antwerp
Faculty of Medicine and Health Sciences
GHENT UNIVERSITY
PAIN IN MOTION

Stelling 7

Table 1. Shoulder laxity tests

Test	Direction of laxity	Cut-off value
Sulcus sign	Inferior	>2 cm [43]
Gagey hyperabduction test	Inferior	>105° [44]
Anterior/posterior load and shift	Anterior/Posterior	Grade 2 or 3 [45]
Passive external rotation in supine	Anterior	>90° [46]
Active external rotation in standing	Anterior	>85° [46]
Posterior jerk	Posterior	Positive if a clunk is felt [47]

MDI

FROZEN SHOULDER

Stelling 7

BUT…

Stelling 7

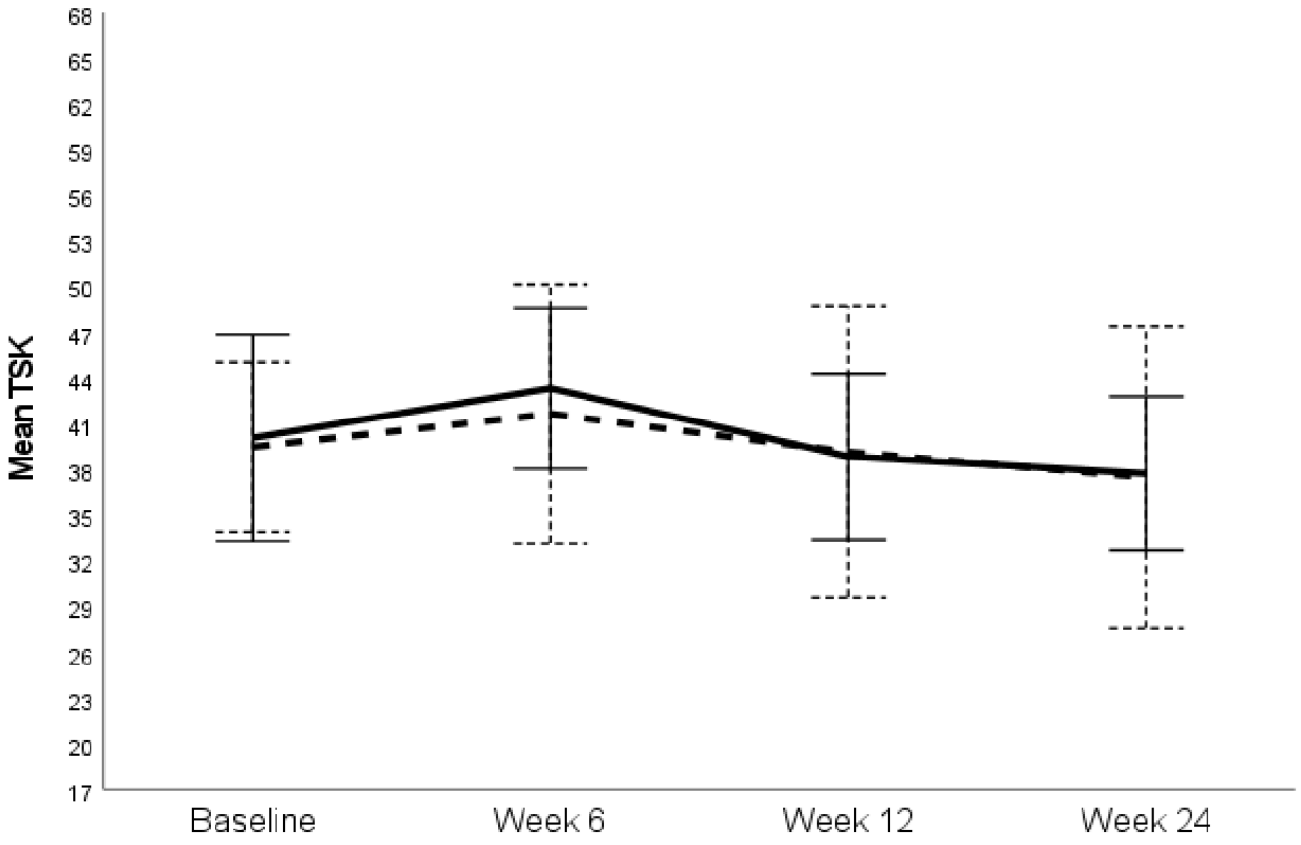

University of Antwerp
Faculty of Medicine and Health Sciences
GHENT UNIVERSITY
PAIN IN MOTION

MDI

FROZEN SHOULDER

Stelling 7

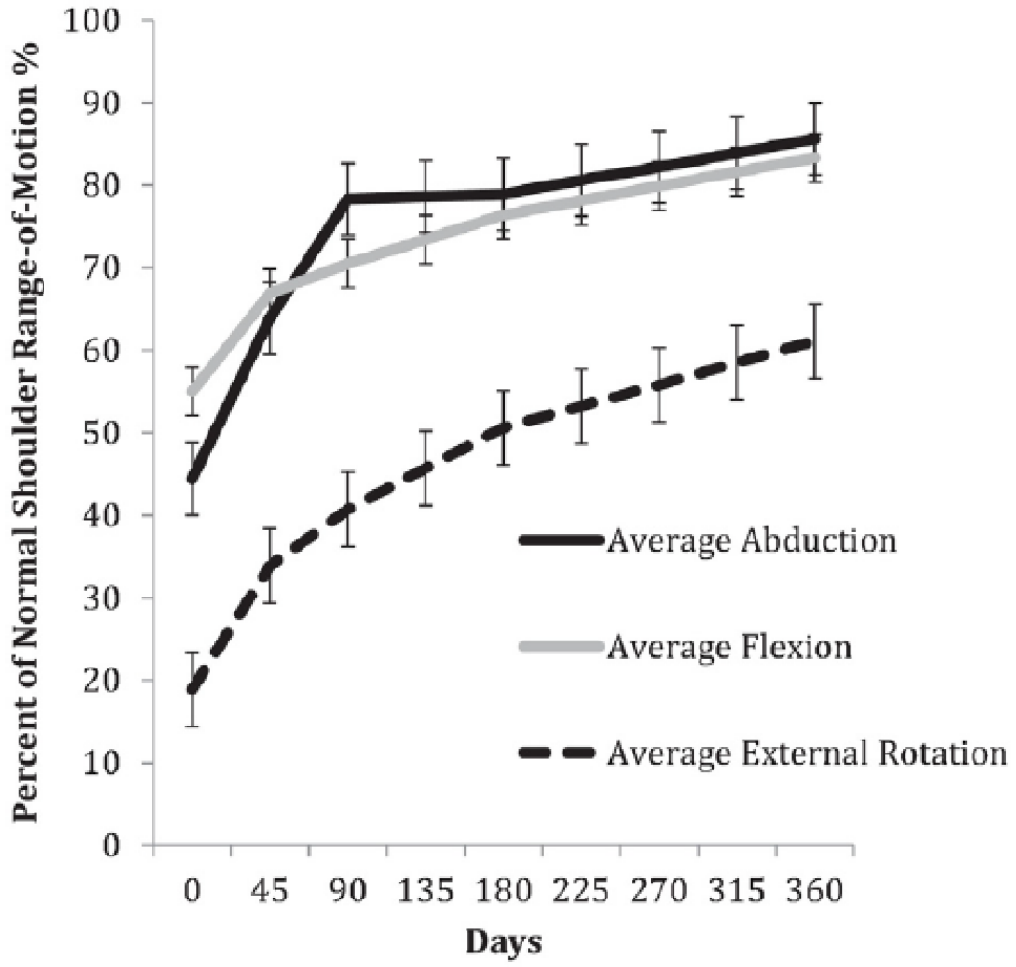

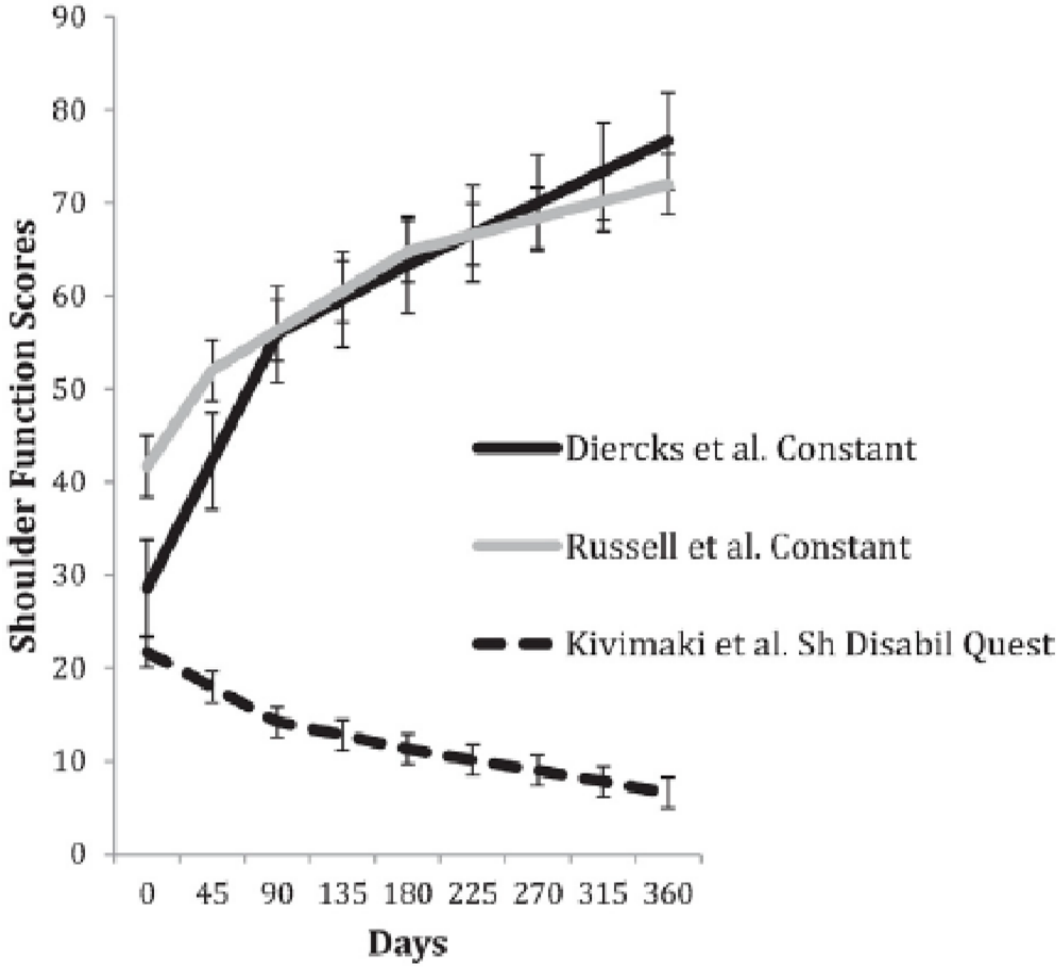

Wong, 2017

MDI

FROZEN SHOULDER

Faculty of Medicine and Health Sciences
GHENT UNIVERSITY
PAIN IN MOTION

Stelling 7

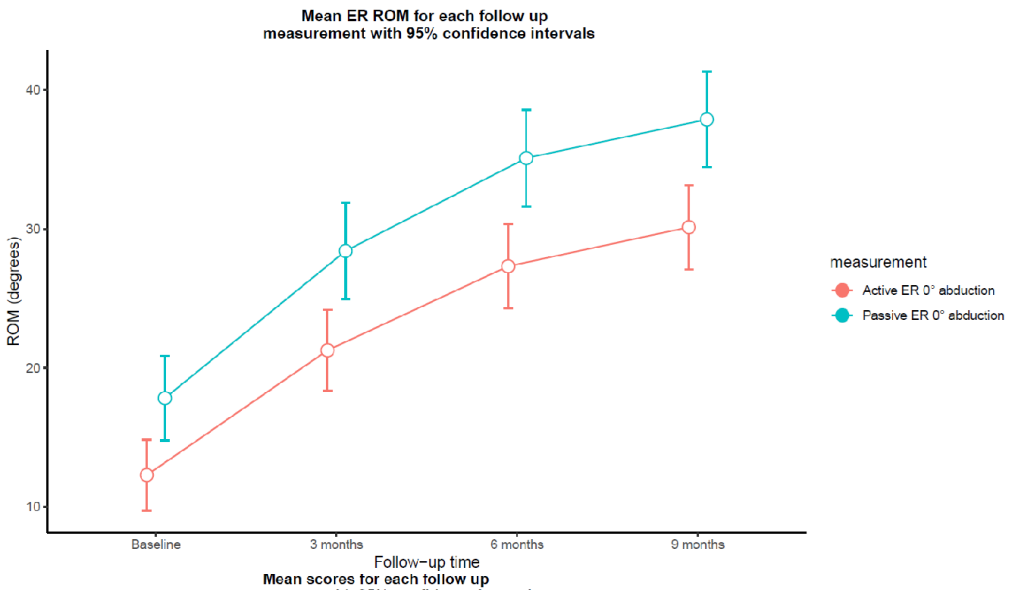

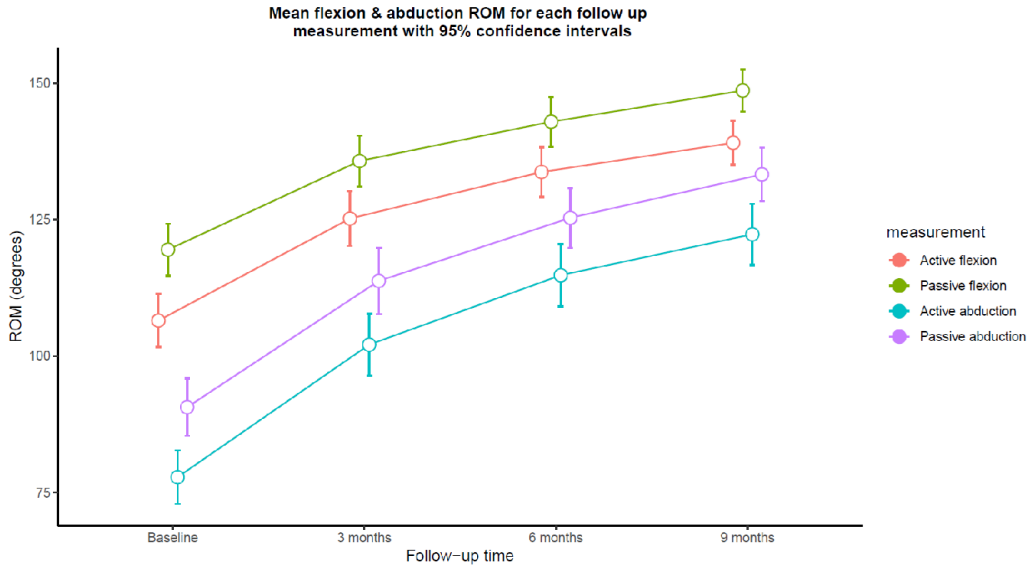

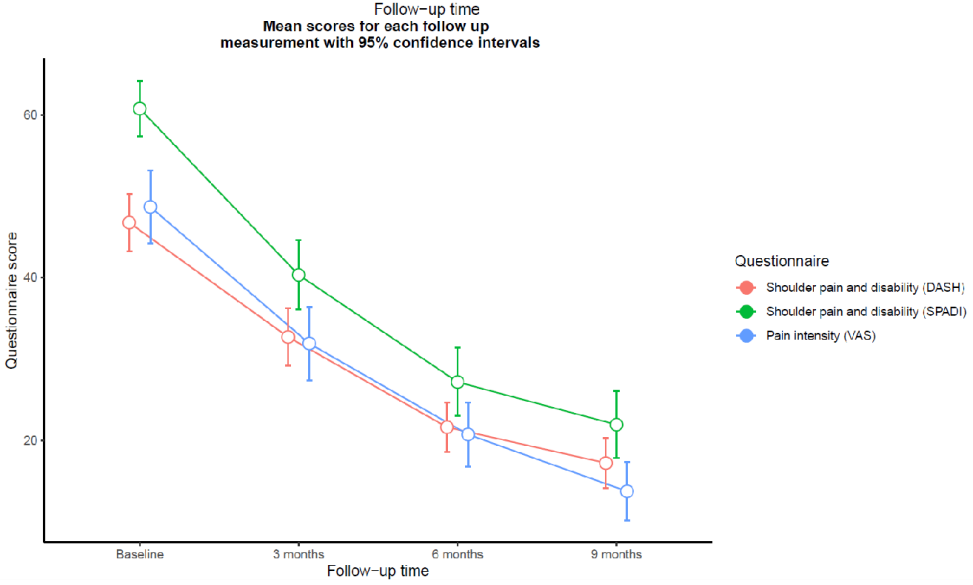

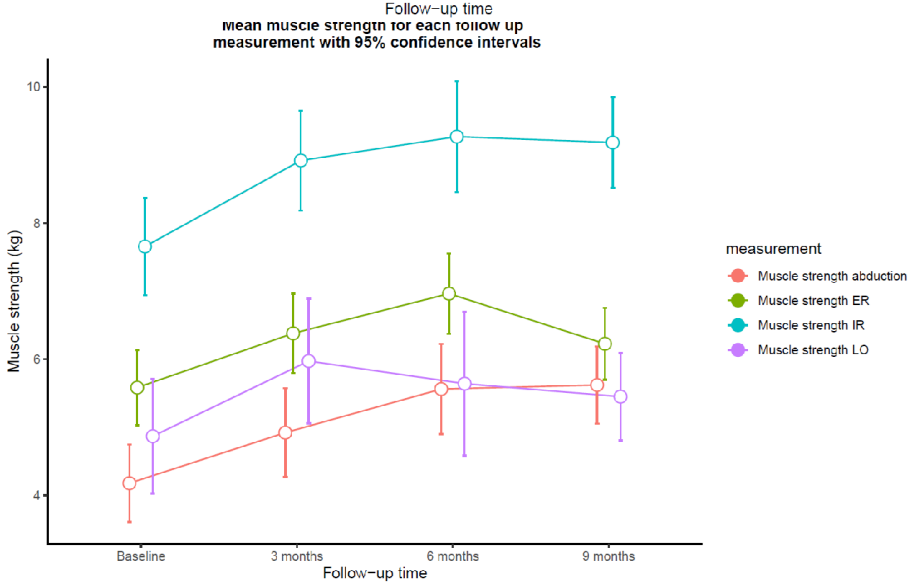

Unpublished data

MDI

FROZEN SHOULDER

Stelling 7

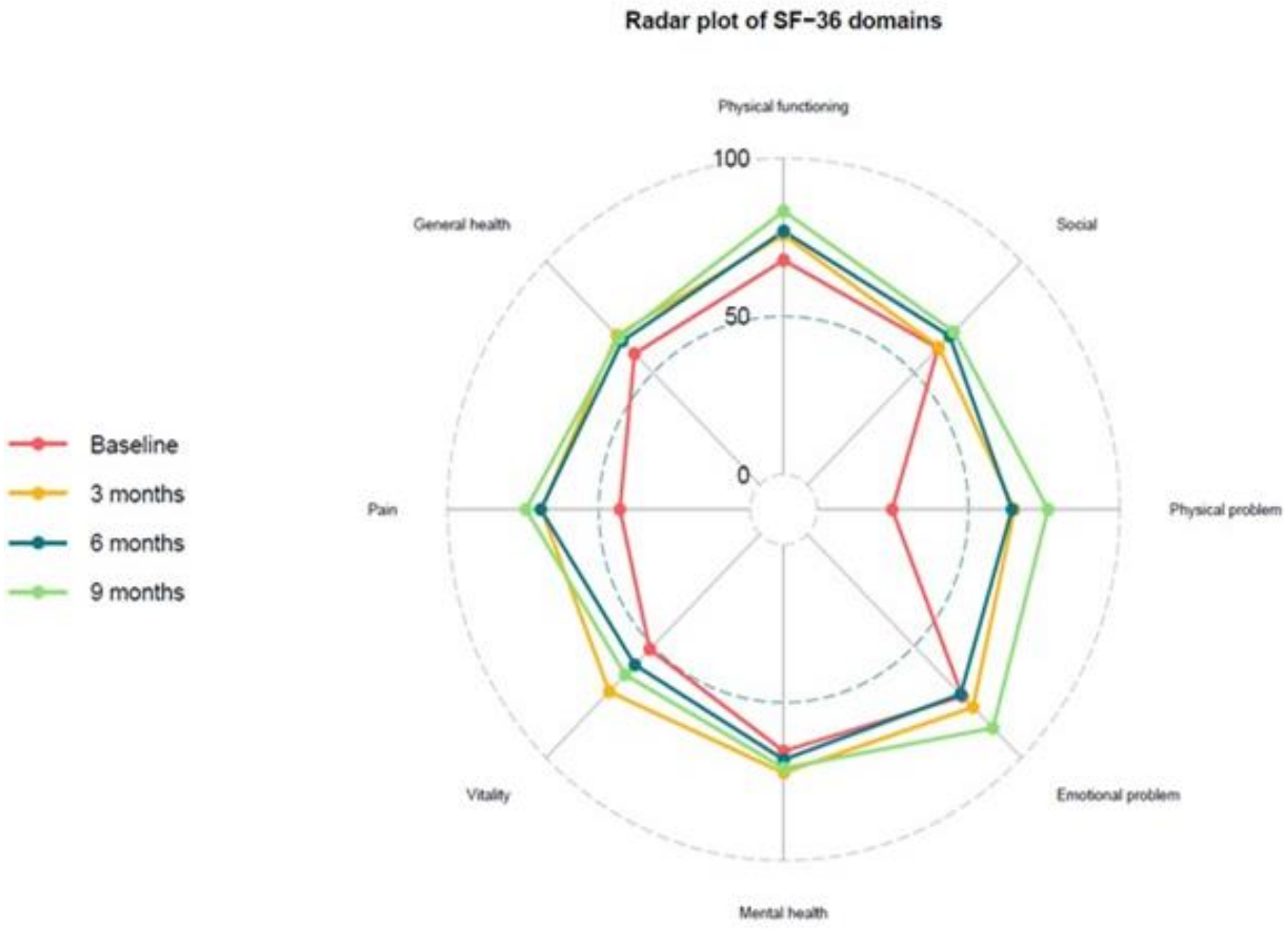

Unpublished data

MDI

FROZEN SHOULDER

University of Antwerp
Faculty of Medicine and Health Sciences
GHENT UNIVERSITY
PAIN IN MOTION

Stelling 7

Definitie self-limiting?

1 studie normale ROM in 1 richting zonder gesuperviseerde behandeling

Volledig herstel van objectief gemeten functie is niet consistent aanwezig

Licht pijnlijke en beperkte schouder

Ernstige symptomen

Shaffer, 1992; Hand, 2008; Robinson, 2012; Wong, 2017

Stelling 7

Voordelen vroege CSI

Pijn

Inflammatie

(myo)fibroblasten

Timing

CSI

Versus

Fysio/kinesitherapie

Mertens, 2021

University of Antwerp | Faculty of Medicine and Health Sciences
GHENT UNIVERSITY
PAIN IN MOTION

MDI

FROZEN SHOULDER

Stellingen

1) Onderliggende aandoeningen van MDI
2) Autonome symptomen van de hyp*mobiele schouder
3) Verstoorde scapulaire kinematica
4) Scapulaire kinematica MDI
5) Scapulaire kinematica FS
6) Pathobiomechanica FS
7) Foute geruchten rond de hyp*mobiele schouder
8) Interventies FS
9) Oefentherapie MDI

Stelling 8

Welke van de onderstaande interventies wordt best NIET gedaan bij een frozen shoulder?

- Oefentherapie
- Passieve mobilisaties
- Actieve mobilisaties
- Alle bovenstaande opties

Start the presentation to see live content. For screen share software, share the entire screen. Get help at **pollev.com/app**

Welke van de onderstaande interventies wordt best NIET gedaan bij een frozen shoulder?

Oefentherapie

Passieve mobilisaties

Actieve mobilisaties

Alle bovenstaande opties

Start the presentation to see live content. For screen share software, share the entire screen. Get help at **pollev.com/app**

Welke van de onderstaande interventies wordt best NIET gedaan bij een frozen shoulder?

Oefentherapie

Passieve mobilisaties

Actieve mobilisaties

Alle bovenstaande opties

Start the presentation to see live content. For screen share software, share the entire screen. Get help at **pollev.com/app**

Stelling 8

(myo)fibroblasten

Freezing fase

Inflammatie

Ryan, 2016; Mertens, 2021

University of Antwerp | Faculty of Medicine and Health Sciences
GHENT UNIVERSITY
PAIN IN MOTION

Stellingen

1) Onderliggende aandoeningen van MDI
2) Autonome symptomen van de hyp*mobiele schouder
3) Verstoorde scapulaire kinematica
4) Scapulaire kinematica MDI
5) Scapulaire kinematica FS
6) Pathobiomechanica FS
7) Foute geruchten rond de hyp*mobiele schouder
8) Interventies FS
9) Oefentherapie MDI

Stelling 9

Welke van onderstaande oefeningen wordt best NIET gedaan bij MDI in kader van GJH?

- Met gewichtje van 0.5 kg elevatie in scapulair vlak
- Elevatie met maximale schrug
- Isometrische schouder extensie
- Wall slide tegen weerstand van theraband

Start the presentation to see live content. For screen share software, share the entire screen. Get help at **pollev.com/app**

Welke van onderstaande oefeningen wordt best NIET gedaan bij MDI in kader van GJH?

Met gewichtje van 0.5 kg elevatie in scapulair vlak

Elevatie met maximale schrug

Isometrische schouder extensie

Wall slide tegen weerstand van theraband

Start the presentation to see live content. For screen share software, share the entire screen. Get help at **pollev.com/app**

Welke van onderstaande oefeningen wordt best NIET gedaan bij MDI in kader van GJH?

Met gewichtje van 0.5 kg elevatie in scapulair vlak

Elevatie met maximale schrug

Isometrische schouder extensie

Wall slide tegen weerstand van theraband

Start the presentation to see live content. For screen share software, share the entire screen. Get help at **pollev.com/app**

Stelling 9

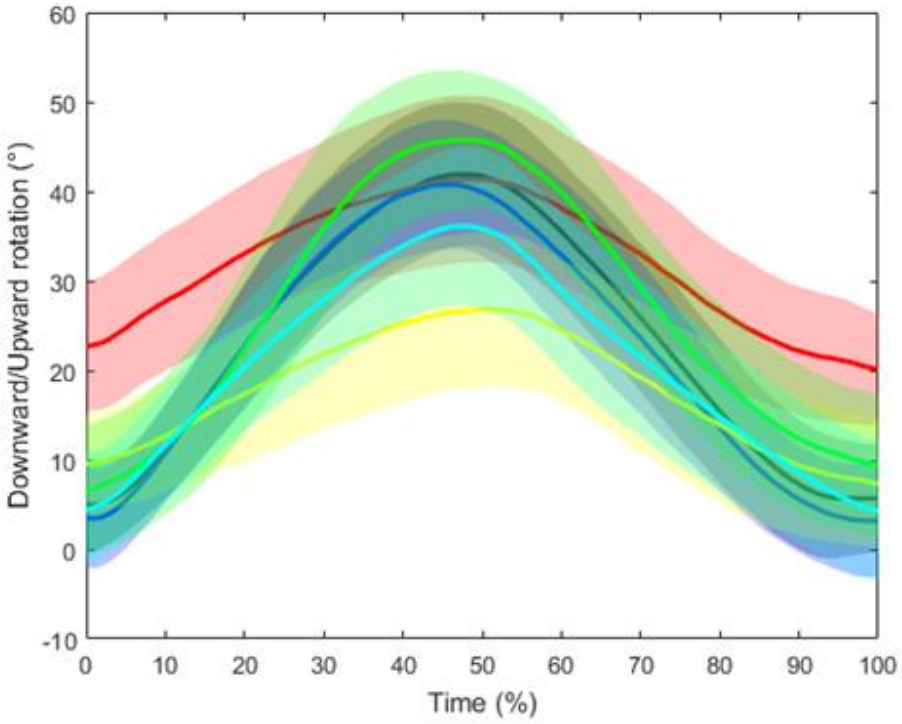

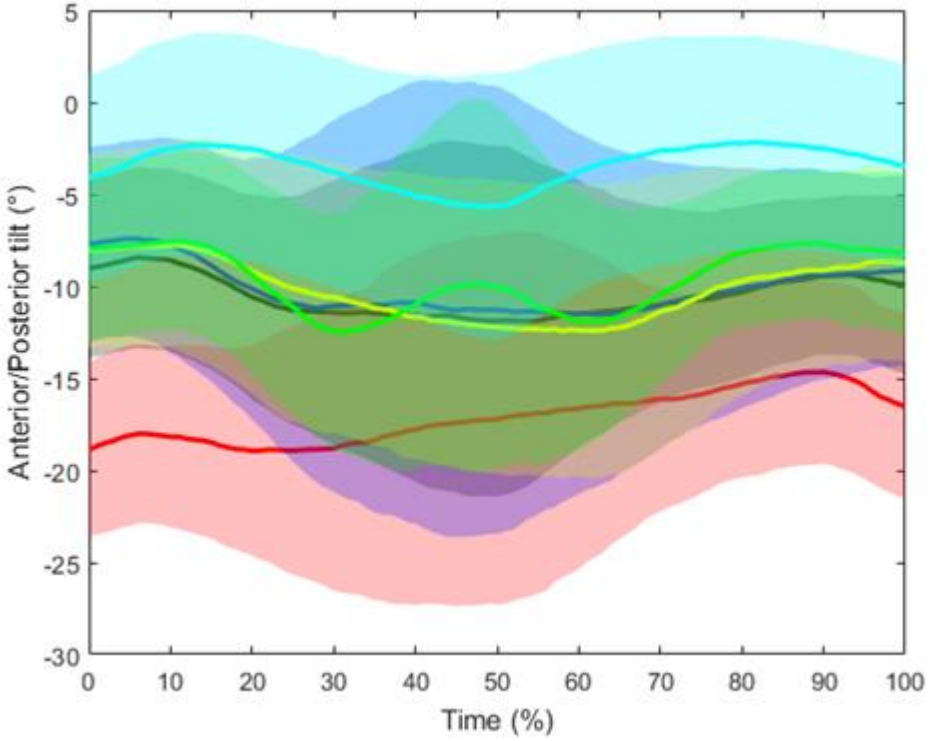

MDI

FROZEN SHOULDER

University of Antwerp
Faculty of Medicine and Health Sciences
GHENT UNIVERSITY
PAIN IN MOTION

Valentien.Spanhove@UGent.be

Michel.mertens@uantwerpen.be

@ValentienSp

@michelmertens4

Valentien Spanhove

Michel Mertens

University of Antwerp
Faculty of Medicine and Health Sciences
GHENT UNIVERSITY
PAIN IN MOTION